

RESEARCH

Open Access



# The protective role of olive oil against gibberellic acid-induced embryotoxicity at prenatal stages of mice

El-Sabry Abu Amra, Fakhr El Din M. Lashein\*, Amin A. Seleem and Manar M. Saleh

## Abstract

**Background:** Gibberellic acid (GA3) is a plant growth regulator used to improve the quality of crops but its residues in food causes many hazardous effects. In contrast, olive oil has registered several health benefits including antioxidant, anti-inflammatory, and anti-cancer. Thus, the present study suggests the use of olive oil as a natural food source to counteract the GA3 toxicity during mice development. In a preliminary experiment, 18 mature females were classified into control and GA3-treated subgroups with ascending doses of GA3 (55, 110, 240, 480, 960 mg/kg B.W.) for 2 weeks. In the main experiment, 20 pregnant females at the 7th day of gestation were divided into four groups: G1 is control, G2 treated orally with GA3 (55 mg/kg), G3 treated with olive oil, and G4 treated with GA3-olive oil. The pregnant females were dissected at prenatal stages at E14 and E18 of gestation.

**Results:** The high doses of GA3 in the preliminary experiment showed decrease of uterine folds, reduction of carbohydrates content and TNFR2 expression of the uterine glands, degeneration of the ovarian follicles, blood vessels congestion, and altered TNFR2 expression in oocyte membrane as compared with the control. In the second experiment, GA3-treated embryo at E14 and E18 revealed histopathological changes and altered TNFR2 immunostaining in the developing liver, kidney, and skin tissues. Treatment of GA3 with olive oil improves the negative effects induced by GA3.

**Conclusion:** The study concluded that a supplementation rich diet with olive oil creates a protective effect against gibberellic acid-induced embryotoxicity during pregnancy.

**Keywords:** Gibberellic acid, embryotoxicity, olive oil, TNFR2

## Background

Plant growth regulators (PGRs) usually are defined as endogenous plant hormones which are produced naturally by plants and are essential for regulating growth, formation of leaves and flowers, elongation of stems, and development and ripening of fruits. PGRs are classified into 5 types as auxins, gibberellins, cytokinins, ethylene, and abscisic acid. The gibberellins represent the important item of plant growth hormones. Gibberellins were discovered isolated whereas there are at least 136 Gibberellin types (Boğa et al., 2009). Gibberellins (GAs) are

plant hormones which control various processes such as stem elongation, stem germination, dormancy, flowering, sex expression, enzyme induction, and fruit senescence (Rios-Irube, et al., 2011; Rangaswamy, 2012). Gibberellic acid (GA3) is accumulated in the soil for months (Schwechheimer and Willige, 2009). Exposure to residues of GA3 as a result of consumption of different kinds of exposed vegetables and fruits causes toxicity and hazardous effects on the health of human and animals (Tomlin, 2004). GA3 has been documented to alter the antioxidative systems and production of free radicals in some organs (Celik and Tuluçe, 2006). GA3 is considered carcinogenic and induce tumor formation (El-

\* Correspondence: [flashein@yahoo.com](mailto:flashein@yahoo.com)

Faculty of Science, Zoology Department, Sohag University, Sohag, Egypt

Mofty et al., 1994). It affects the sexual differentiation and the fecundity of mammals (Ozmen et al., 1995).

Vegetable oils are considered an important source of antioxidants (Ramadan and Moersel, 2006). Olive oil is obtained from the fruit *Olea europaea* and has been used since ancient times in the traditional medicine, skin protectants, cosmetics, soaps, bath oils, creams, and perfumes (Brun, 2000). Olive oil contains multiple bioactive and antioxidant components, e.g., vitamins (alpha- and gamma-tocopherol and betacarotene), phytosterols, squalene, pigments, terpenic acids, flavonoids (luteolin and quercetin), polyphenols, unsaturated fatty acids (oleic, linoleic and linolenic acids), microconstituents (e.g., phenolic compounds in the unsaponifiable fraction), and micronutrients (A, E and b-carotene) (Visioli and Galli, 2002; Covas, 2007). The healthful properties of olive oil are attributed to its contents of a series of phenolic components, e.g., hydroxytyrosol, tyrosol, oleuropein, and ligostride (Omar, 2010). In addition, olive oil contains decarboxymethyl ligostride aglycone that is considered a natural anti-inflammatory substance which counteracts the inflammatory processes (Parkinson and Keast, 2014; Rosillo et al., 2014). Pharma-nutritional evidence from the last decade indicates that olive oil has an important role in cardioprotection and prevents neurodegenerative diseases, e.g., Alzheimer's disease (AD), Parkinson's disease (PD), and mitigating the spinal cord injury (SCI). In addition, olive oil has antimicrobial, hypoglycemic, anti-inflammatory, antioxidant, and anti-hypertension and is beneficial to wound healing process and antiviral (Crespo et al., 2018; Figueiredo-González et al., 2018). Olive oil was documented as having anti-oncogenic activity and anti-cancer especially colorectal and breast cancer (Menendez and Lupu, 2006; Pelucchi et al., 2011) and decreases chronic disease such as cardiovascular diseases (CVD) (Ruiz-Canela and Martínez-González, 2011) and atherosclerosis (Kok and Kromhout, 2004). Health-protective effects of olive oil have been traditionally due to its high content of monounsaturated fatty acid mostly in the form of oleic acid (Escrich et al., 2011; Bermudez et al., 2011). Olive oil biophenols have potential preventive actions against cancer by inhibition of cell proliferation and tumor progression (Crespo et al., 2018). Therefore, the aim of the work is to investigate the counter effect of olive oil against GA3-induced embryotoxicity during prenatal stages of mice.

## Materials and methods

### Gibberellic acid (GA3)

Berelex tablet (10 g) contains 10% GA3 and manufactured by Valent BioSciences Corporation, Illinois, USA.

Stock solution was prepared in saline and renewed as required during the experimental period.

### Olive oil

Virgin olive oil (VOO) was purchased from a local market. VOO contained 68.23% of monounsaturates (mainly oleic acid), 16.29% of saturates (palmitic and stearic acids), and 14.21% of polyunsaturated fatty acid.

### Experimental procedure and animal grouping

Immature mice (3 weeks old) *Mus musculus* were obtained from animal house of Sohag University. Animals were acclimatized in laboratory at normal light and temperature conditions with free access to food and water till maturity. In a preliminary experiment, 18 mature females were divided into control and GA3 oral daily exposed for 1 week with ascending doses of GA3 (55, 110, 240, 480, 960 mg/kg B.W.). The exposed females (3 animals each) for each dose were mated with one mature male with continuous dosing for an additional week. Females were dissected for pregnancy clarification. In the second experiment, 20 pregnant female mice (25–30 g) at the 7th day of gestation were divided into four groups (five females in each group). Group 1 served as controls. Group 2 received GA3 through drinking water (55 mg/kg equivalent to 1/100 of LD 50) (Troudi et al., 2011; El-Sayyed et al. 2012). Group 3 was treated with olive oil (16.6 ml/kg B. W.) via gastric gavage. The dose of olive oil is relatively similar to the Mediterranean diet style of olive oil consumption (Esposito et al., 2004). Group 4 combined administered with GA3 and olive oil. The experimental groups were kept under experimentation from the 7th day of pregnancy up to the 18th day. The use of studied animals and experimental protocol complied according to the guidance of ARRIVE guidelines and the Institute of Laboratory Animal Resources (ILAR, 1986; Kilkenny et al., 2010).

### Histological and immunohistochemical examinations

The tissues from the first experiment (ovaries and uteri of control and GA3-treated groups) and from the second experiment (embryos at E14 and E18 at studied groups) were fixed in Carnoy's fixative. The fixed tissues were dehydrated in absolute ethanol, cleared in methyl benzoate, and infiltrated in paraffin wax. The paraffin blocks of studied tissues were cut at 5 µm thick by microtome (RM 2125RTS; Leica Biosystems, Shanghai, China). The paraffin sections were mounted on glass slides and dried at 40 °C in an oven for 3 days. Selected sections of the first experiment (uterus, ovary) and from the second experiment (developing liver, kidney, skin at E14 and E18) were stained with hematoxylin and eosin for general histological picture and with periodic acid Schiff's (PAS)

reaction for polysaccharide detection (Drury and Wallington, 1976).

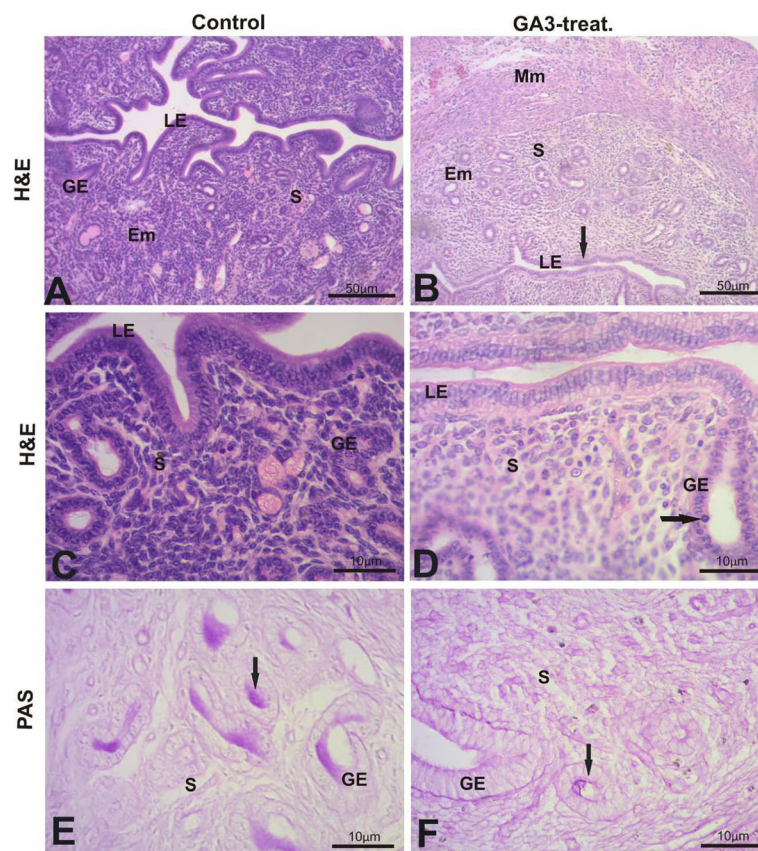
In the immunohistochemical study, the selected sections of the first experiment (uterus, ovary) and from the second experiment (developing liver, kidney, skin at E14 and E18) were mounted on positive slides (Superfrost/Plus). According to the manufacturer's protocol of Spring Bioscience company, the selected sections were deparaffinized in xylene, rehydrated in descending alcohol series (100, 90, 70, 50%), and retrieved for re-antigenicity using citrate buffer (10 mM, pH = 6) in an oven at 100 °C for an hour (Buchlowalow and Bocker, 2010). Sections were treated for 10 min with 3% hydrogen peroxide block and then with protein block (phosphate buffer solution, pH 7.6, with 0.5% BSA, 0.5% casein, and less than 0.1% sodium azide) for 10 min to block nonspecific background staining. Sections were incubated with primary antibody (tumor necrosis factor receptor 2, TNFR2) (Rabbit polyclonal, Spring Bioscience, USA). The washing step was carried out by using phosphate buffer (pH = 7.4) for three times. Sections were incubated with biotinylated goat anti-

polyvalent in phosphate buffer for 30 min. Then, sections were incubated with Streptavidin Peroxidase for 30 min. Sections were immersed in freshly preparation of solution (20 µl of DAB Chromogen (3, 3'-diaminobenzidine) + 1 ml of DAB substrate) for 15 min. Sections were dehydrated in ascending series of ethanol (50%, 70%, 90%, 100%). The clearing process occurred by xylene and mounting by using DPX mounting media. Selected sections of adult tissues (uterus, ovary) and developing tissues at E14 and E18 days (liver, kidney, skin) were photographed as required. Imaging were made using a light microscope (Axiolab Standart 20, Carl Zeiss, Germany) provided with camera (Axion Cam, Carl Zeiss, Germany).

## Results

### Uterine and ovarian tissues

The histological structure of the control uterus showed the normal uterine folds in the endometrium (Fig. 1a, c). GA3-treated group (110 mg/kg B.W.) provoked a decrease of uterine folds and an increase of pyknotic cells (Fig. 1b, d). The uterine gland of control uterus showed



**Fig. 1** Photomicrographs of histological sections (H&E and PAS). Control uterus showed normal structure (**a, c**). GA3-treated showed a decrease of uterine folds and an increase of pyknotic cells (arrow, **b, d**). Uterine gland of GA3-treated group showed a decrease of PAS content (arrow, **f**) as compared to control PAS (arrow, **e**). MM, myometrium; EM, endometrium; LE, luminal epithelium; S, stroma; GE, glandular epithelium. Scale bar = 50 µm (**a, b**) and 10 µm (**c–e**)

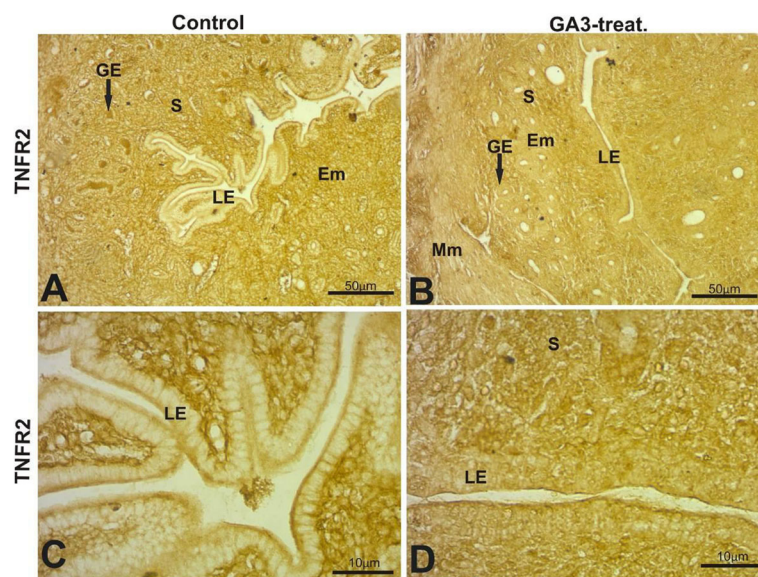


a positive carbohydrate reaction (PAS) (Fig. 1e), whereas the GA3-treated group (110 mg/kg B.W.) showed negatively staining of carbohydrate contents in the uterine glands (Fig. 1f). Immunohistochemical study showed positive localization of TNFR2 in control uterine glands (Fig. 2a) that was absent in the luminal epithelium except its apical cell surface (Fig. 2c). GA3-treated group (110 mg/kg B.W.) showed decrease in the TNFR2 expression in the uterine glands (Fig. 2b) and alteration in the expression of luminal epithelium that was detected throughout the cells (Fig. 2d). Treating animals with GA3 for a continuous 2 weeks causes histopathological alterations in the ovary including severe degeneration of the ovarian follicles and congestion of blood vessels (Fig. 3b, d) as compared to the normal structure in control (Fig. 3a, c). Degenerated follicles in the ovary of GA3-treated group showed alteration in the carbohydrates content (Fig. 3f) as compared to the normal localization in the oocyte membrane of control (Fig. 3e). TNFR2 expression was detected in the zona pellucida of control ovary (Fig. 3g), whereas ovarian toxicity with GA3 showed undistinguished TNFR2 expression in zona pellucida with an increase in the expression of zona granulosa cells (Fig. 3h).

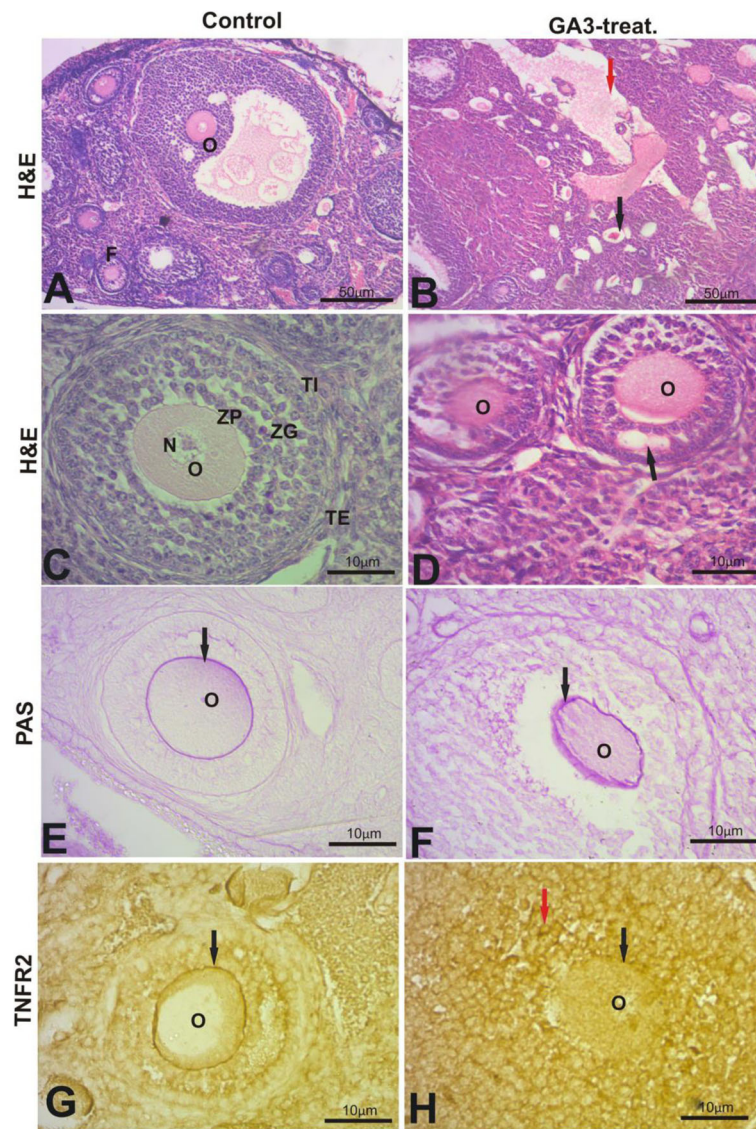
# Liver

The control liver at E14 of gestation showed normal hematopoietic tissue. PAS-stained sections showed positive megakaryocytes (Fig. 4b). TNFR2 expression was localized in the blood vessel of the developing liver with

pale or faint expression in hepatic parenchyma (Fig. 4c). In GA3-treated embryo, the developing liver showed vacuolation of hematopoietic tissue that was associated with increase inflammatory cells (Fig. 4d). GA3-treated embryo showed an increase in the abundance of megakaryocytes in the PAS-stained sections (Fig. 4e) and downregulation of TNFR2 expression (Fig. 4f) as compared to control. The olive oil-treated group elucidated similarity to the control group regarding the structure of hematopoietic tissue, positive megakaryocytes, in addition to increased TNFR2 expression along to the endothelial lining of the blood vessels (Fig. 4g–i). The olive oil-treated GA3 group showed improvement in the alterations induced by GA3 (Fig. 4j–l). The developing liver at E14 of gestation in the studied groups showed a negative stain of glycogen. The control liver at E18 of gestation showed hematopoietic tissue and developing hepatocytes which contact with each other to form hepatic cords (Fig. 5a). Hepatocytes of the developing liver in control revealed regularly positive stainability to carbohydrate content (PAS staining) throughout the hepatic parenchyma (Fig. 5b). TNFR2 expression was observed in the blood vessel and in some hepatocytes (Fig. 5c). The hematoxylin and eosin-stained sections of the developing liver at E18 in GA3-treated embryo showed pale-staining of less viable tissue, difficulty to differentiate the nuclei and decline in erythropoietic activity (Fig. 5d). In GA3-treated embryos, the developing liver revealed depletion of hepatic parenchyma in PAS stainability (Fig. 5e) and downregulation of the TNFR2



**Fig. 2** Photomicrographs of immuno-stained sections of uterine tissues showed TNFR2 expression in the control uterine gland (arrow, **a**). GA3-treated group showed a decrease in TNFR2 expression in the uterine gland (arrow, **b**). High magnification field showed alteration in TNFR2 expression of the endometrium (**d**) as compared to control (**c**). MM, myometrium; EM, endometrium; LE, luminal epithelium; S, stroma; GE, glandular epithelium. Scale bar = 50  $\mu$ m (**a**, **b**) and 10  $\mu$ m (**c**, **d**)



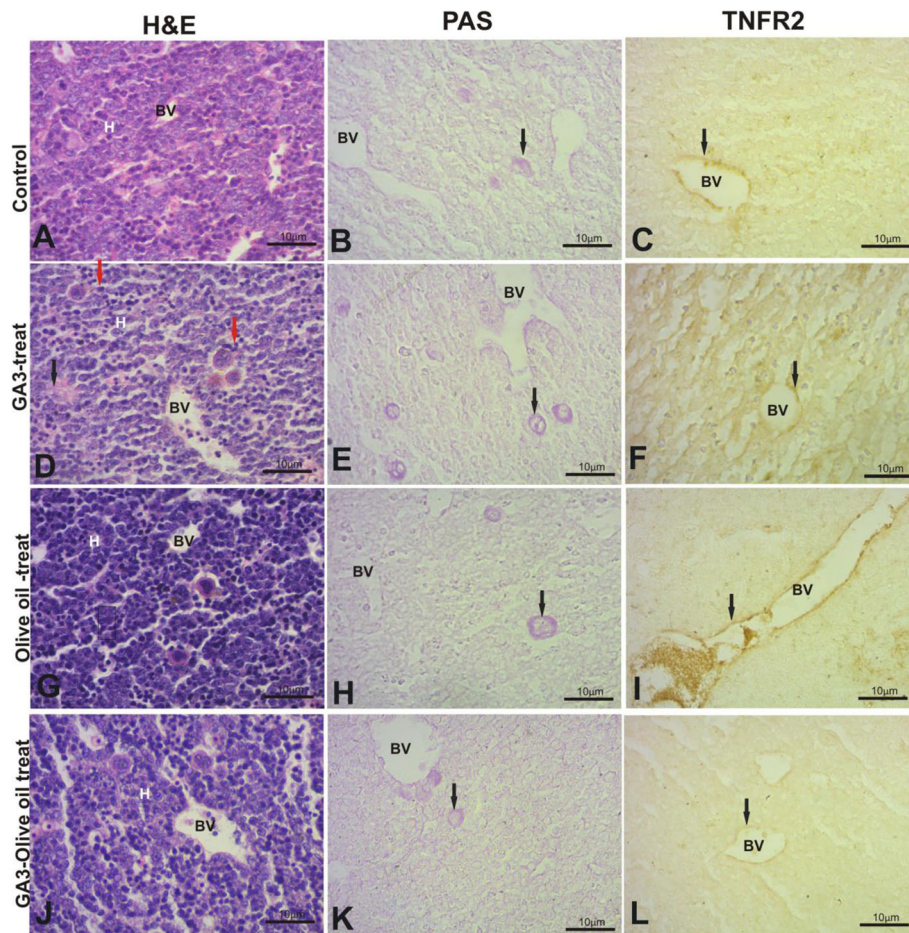
**Fig. 3** Photomicrographs of H&E-, PAS-, and TNFR2 immuno-stained sections in the ovary. Normal histological structure was observed in control ovary (**a, c**). GA3-treated group showed congestion of blood vessel (red arrow, **b**), degeneration of the follicles (black arrow, **b**), and vacuolation (black arrow, **d**). GA3-treated group showed alteration in the carbohydrates content (PAS) (arrow, **f**) as compared to the normal localization in the zona pellucida of control ovary (arrow, **e**). TNFR2 expression was detected in the zona pellucida of control ovary (arrow, **g**), whereas GA3-treated ovary showed undistinguished TNFR2 expression in zona pellucida (black arrow, **h**) with increase the TNFR2 expression in zona granulosa cells (red arrow, **h**). O, oocyte; F, follicle; N, nucleus; ZP, zona pellucida; ZG, zona granulosa; TI, theca interna; TE, theca externa. Scale bar = 50  $\mu$ m (**a, b**) and 10  $\mu$ m (**c-h**)

expression (Fig. 5f) as compared to control. In olive oil-treated embryos, the histological (H&E) and histochemical (PAS) stains of developing liver at E18 revealed similarity to control group (Fig. 5g, h). An increase of TNFR2 expression was observed in the hepatic tissue of olive oil-treated embryos (Fig. 5i) as compared to control. The GA3-olive oil-treated group showed improvement of the alterations that is induced by GA3 at the level of histology (H&E), histochemistry (PAS), and immunohistochemistry (TNFR2) (Fig. 5j-l).

### Kidney

The developing kidney at E14 of gestation in the studied groups showed glomeruli and tubules. There are no abrupt histopathological changes that were observed in the developing kidney at E14 at the level of H&E, PAS, and TNFR2 stains in the studied groups, GA3 (Fig. 6d-f), olive oil (Fig. 6g-i), and GA3-olive oil (Fig. 6j-l), as compared to control (Fig. 6a-c). The control kidney at E18 of gestation showed well-developed Bowman's capsules, glomeruli, and tubules (Fig. 7a). PAS-stained sections of





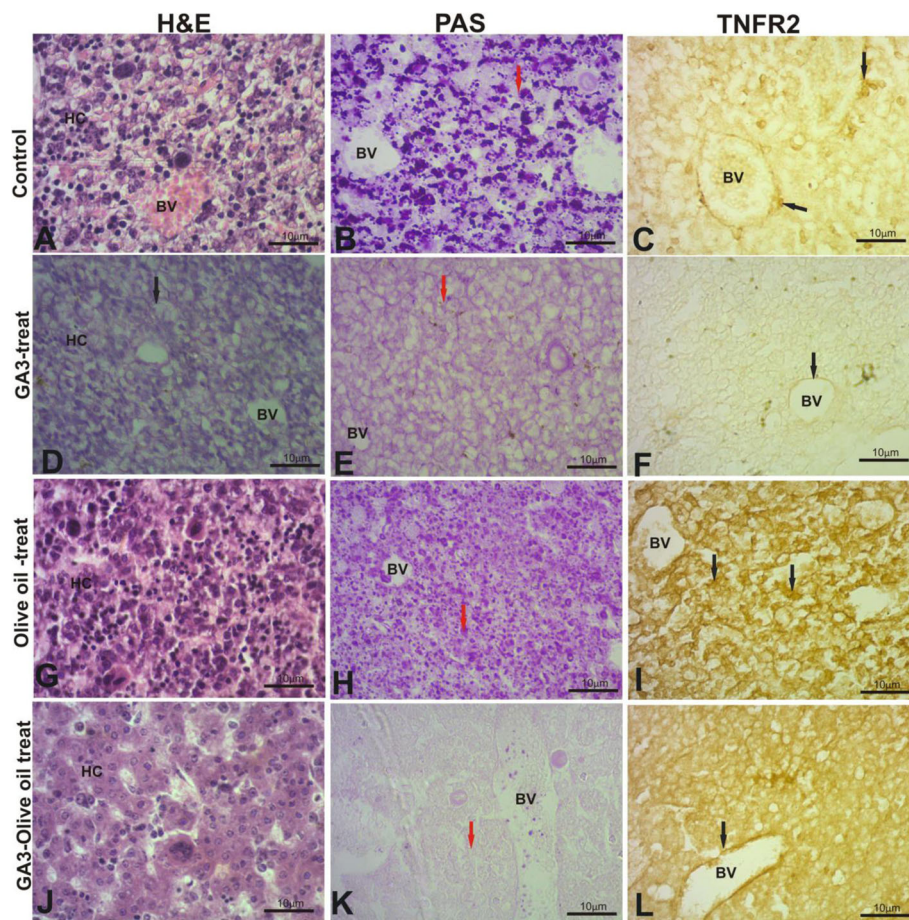
**Fig. 4** Photomicrographs of H&E-, PAS-, and TNFR2-stained sections of developing liver at E14. The control liver showed normal structure of hematopoietic tissue, positive megakaryocytes in PAS reaction (black arrow, **b**), and TNFR2 expression was localized in blood vessel (black arrow, **c**). GA3-treated group exhibited loosely arranged hematopoietic cells (black arrow, **d**), pyknotic cells (red arrow, **d**), increase the number of megakaryocytes in PAS reaction (arrow, **e**), and decrease TNFR2 expression (arrow, **f**). Olive oil-treated embryo did not exhibit any histopathological alteration (**g**, arrow **h**, arrow **i**). GA3-olive oil-treated embryo showed improvement in the GA3 alterations (**j**, arrow **k**, arrow **l**). BV, blood vessel; H, hematopoietic. Scale bar (**a**–**l**) = 10  $\mu$ m

control kidney at E18 revealed positively stained brush border of proximal convoluted tubules and glomeruli (Fig. 7b). TNFR2 expression was localized in the kidney tubules (Fig. 7c). The kidney of GA3-treated embryos revealed pale-staining, degeneration of renal tubules, and shrinkage of renal corpuscles (Fig. 7d) as compared to the control. Depletion of polysaccharides in brush border and the glomeruli (PAS stain) (Fig. 7e) and downregulation of TNFR2 expression were observed in the kidney of GA3-treated embryos. Olive oil-treated embryo showed similar kidney structure of control but an increase in the expression of TNFR2 was noted (Fig. 7g–i). The kidney in the GA3-olive oil-treated embryos revealed improvement in the alterations that is induced by GA3 (Fig. 7j–l).

### Skin

The skin at E14 of gestation showed epidermis and dermis. The epidermal layer is characterized by primordia of hair

follicles that are surrounded by dense mesenchyme of the dermis (Fig. 8a). The carbohydrates were detected in the basement membrane of the epidermis (Fig. 8b). TNFR2 expression was localized in the dermal layer (Fig. 8c). The skin of GA3-treated embryos revealed a thin epidermis with poor development of primordial hair follicles that was associated with vacuolization and pyknotic cells (Fig. 8d). Decrease in the epidermal PAS staining (Fig. 8e) and TNFR2 expression (Fig. 8f) was noted in the GA3-treated embryo. The H&E- and PAS-stained sections in the skin of olive oil-treated embryos showed similar structure to the control (Fig. 8g, h) but an increase of TNFR2 expression was observed (Fig. 8i). Improvement in the histopathological changes was noted in GA3-olive oil treatment (Fig. 8j–l). The control skin at E18 consists of well-differentiated layers: Malpighian, stratum spinosum, stratum granulosum, stratum corneum, and a well-developed hair follicle (Fig. 9a). PAS- and TNFR2-stained skin sections revealed localization of carbohydrates and



**Fig. 5** Photomicrographs of H&E-, PAS-, and TNFR2-stained sections of developing liver at E18. The control liver showed normal structure of hepatic cord, positive carbohydrates (red arrow, **b**), and TNFR2 expression was localized in blood vessel and in some hepatocytes (black arrow, **c**). GA3-treated group exhibited loosely arranged hepatic cords with pale-staining and vacuolation (black arrow, **d**), decrease the PAS reaction (red arrow, **e**), and decrease TNFR2 expression (black arrow, **f**). Olive oil-treated embryo did not exhibit any alteration in H&E and PAS (**g**, arrow **h**) but showed an increase of TNFR2 expression (black arrow, **i**). GA3-olive oil-treated embryo showed improvement in the GA3 alterations (**j**, arrow **k**, arrow **l**). BV, blood vessel; HC, hepatic cords. Scale bar (**a–l**) = 10  $\mu$ m

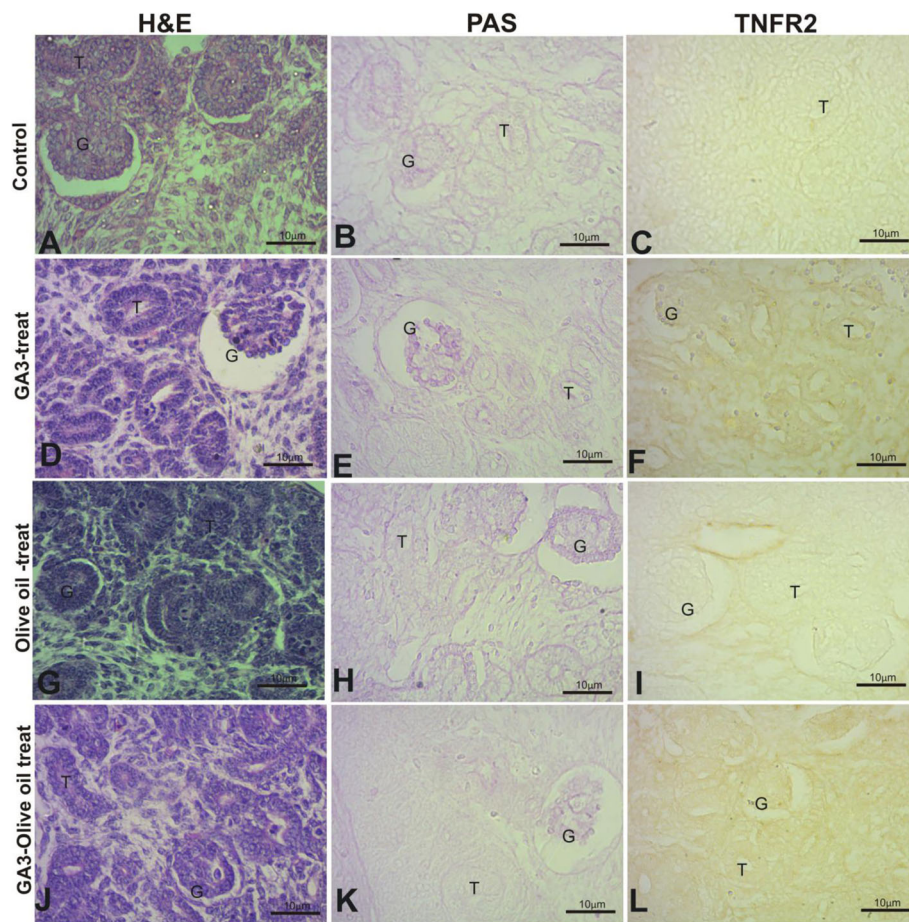
TNFR2 expression in the epidermal layer (Fig. 9b, c). The histological, histochemical, and immunohistochemical alterations induced by GA3 were concomitant with a thin wrinkled epidermis, a less abundant and disorganized hair follicles with shrinkage of dermal papilla and decrease in PAS and TNFR2 expression in the epidermal layer (Fig. 9d–f) as compared to control. H&E- and PAS-stained sections in the skin of olive oil-treated embryo showed similarity to control. High TNFR2 expression was noted in the epidermis and dermis of skin of olive oil-treated embryo (Fig. 9i). The skin of GA3-olive oil-treated embryos showed improvement in the H&E, PAS, and TNFR2 expression as compared with skin of GA3-treated embryo (Fig. 9j–l).

## Discussion

The present study showed histopathological changes after treatment with GA3 in the adult tissues (uterus, ovary) and developing tissues (liver, kidney, skin) of mice

at prenatal stages E14, E18 at the level of histology (H&E), histochemistry (PAS), and immunohistochemistry of TNFR2. Previous studies reported that GA3 induces histopathological and biochemical alterations in the ovary of albino rats at a dose of 50 mg/kg B.W. of GA3 for 4 weeks (Lamfon, 2013). GA3 toxicity was documented in adult rats and their progeny (Troudi et al., 2010). In the same context, GA3 has transplacental passage properties and affects the fetal tissues (Alsemeh et al., 2019). Exposure to GA3 causes teratogenicity in the *Xenopus* embryos and in the albino rat, whereas the live embryos have severe negative effects by accumulation (Boğa et al., 2009; El-Sayyad et al., 2012). GA3 also induces abnormal development of the external morphology and ossification of rat skeleton (El-Sayyad et al., 2012). Oral exposure of GA3 to Wistar rats during late pregnancy, lactation, and early postnatal periods causes histopathological alteration in the suckling rats and their





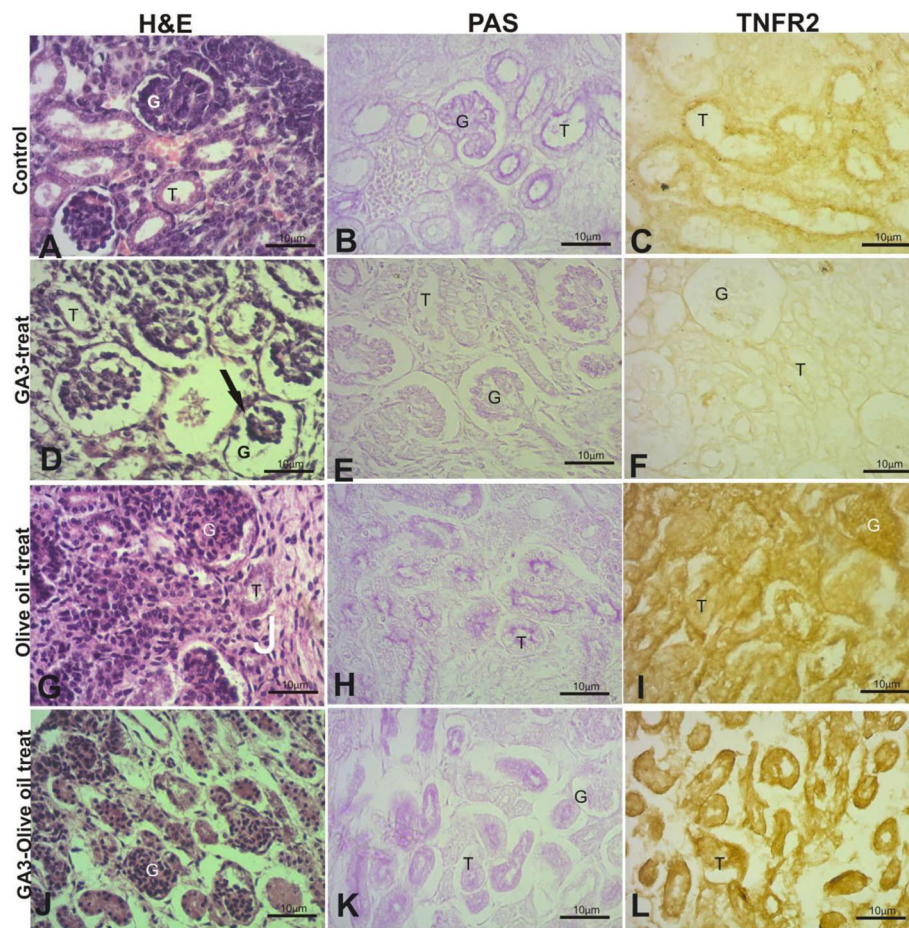
**Fig. 6** Photomicrographs of H&E-, PAS-, and TNFR2-stained sections of developing kidney at E14. The developing kidney at E14 of gestation in the studied groups showed glomeruli (G) and tubules (T). There is no histopathological alteration noted in the developing kidney at E14 at the level of H&E, PAS, and TNFR2 stains in the studied groups; GA3 (**d–f**), olive oil (**g–i**), GA3-olive oil (**j–l**) as compared to control (**a–c**). Scale bar (**a–l**) = 10 μm

mothers (Troudi et al., 2011). Abnormal biochemical parameters of brain, liver, and kidney were reported after exposure to GA3 (Troudi et al., 2012; Abdel Rahm et al., 2017). The harmful effects induced by Gibberellic acid were attributed to inducing oxidative stress, reactive oxygen species (ROS) that oxidize and attack the vital cellular component to initiate or progress the cellular damage (Stadtman and Levine, 2000). Other factors such as impairment of the antioxidant enzymes system, reducing cellular defense system, and production of free radicals that account to the histopathological alteration induced by GA3 were reported (Halliwell and Gutteridge, 1999; Troudi et al., 2010). Exposure to GA3-induced damage of DNA of the cells due to oxidative stress that was caused by reactive oxygen species (Chen et al. 2012). The current study showed a decrease of the carbohydrate contents during the development of the liver, kidney, and skin in the GA3-treated group. Similar reports indicated a failure of energy preservation after

exposure to insecticides. Also, during stress, more energy will be needed to get rid of the toxicants and minimizing the dangerous effects (Sharma and Agarwal, 2004; Seleem, 2019).

Olive oil was found to contain a mix of phenolic compounds such as oleuropein and hydroxytyrosol which have therapeutic capabilities and scavenging abilities, e.g., decrease ROS production, malondialdehyde (MDA), and downregulate of cyclooxygenase 2 (COX-2) expression and inducible nitric oxide synthase (iNOS) (Camargo et al., 2014; Incani et al., 2016). Oleuropein and hydroxytyrosol assert their anti-inflammatory properties by several mechanisms, e.g., effect on cytosolic  $Ca^{2+}$  levels, reduction of cytokines IL- $\alpha$  and TNF- $\alpha$ , decreasing the number of infiltrating neutrophils, and activation T and B lymphocytes (Gong et al., 2009; Zbidi et al., 2009). Oleuropein and hydroxytyrosol showed protective effects on vascular endothelial cells by limiting oxidative injury and inflammatory damage mediated



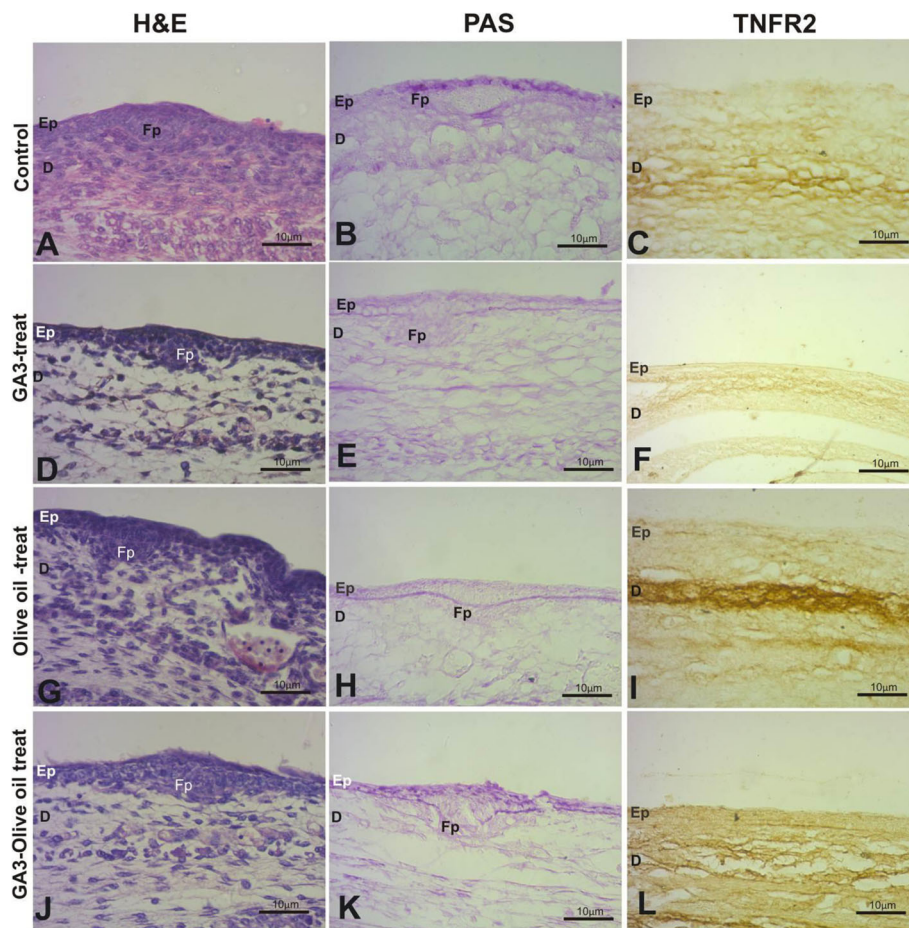


**Fig. 7** Photomicrographs of H&E-, PAS-, and TNFR2-stained sections of developing kidney at E18. The control of developing kidney at E18 of gestation showed glomerulus (G), and tubules (T) (a). The kidney tubules showed positive carbohydrates (PAS reaction) (b) and TNFR2 expression (c). GA3-treated embryos revealed kidney of pale-staining, tubule degeneration, shrinkage of renal corpuscles (arrow, d), decrease stainability of carbohydrates (e) and TNFR2 localization (f). Olive oil-treated embryo showed similar kidney structure such that observed in the control but an increase in the expression of TNFR2 was noted (g–i). The kidney in the GA3-olive oil-treated embryos revealed improvement in the alterations that induced by GA3 (j–l). Scale bar (a–l) = 10  $\mu$ m

by TNF- $\alpha$  Zrelli et al., 2011). Administration of olive oil with hydroxytyrosol is beneficial in acute inflammation and rheumatoid arthritis; it decreases paw edema, bone resorption, inducible nitric oxide, and osteophyte formation, inhibiting cancer cell lines of breast, prostate, and colon (Silva et al., 2015; Rosignoli et al., 2016). In addition, olive oil with its phenolic compound has been shown inhibitory effects on neovascularization and angiogenesis abrogation by inhibition of MMP-2, MMP-9 activity, and downregulation of VEGF expression (Scoditti et al., 2012; Lamy et al., 2014). In the same scenario, ingestion of phenol-rich olive oil exerts positive regulatory effects on neuronal function and chemopreventive effects of DNA damage and modulates the expression of microRNAs in mothers and offspring during pregnancy and reduces inflammatory action that is caused by joint-degenerative and neurodegenerative diseases (Casas-

Agustench et al., 2015; Luceri et al., 2017). Moreover, administration of phenolic-rich olive improves neurologic deficit, counteract age-related dysfunctions, and reduces brain edema and blood-brain barrier permeability (Pitozzi et al., 2012; Rabiei et al., 2013).

Inhibition of TNFR2 expression was noted in the GA3-treated group that might be attributed to losing the viability of cells to synthesize required factors to maintain its normal life function under the stress of GA3 toxicity. A previous study documented the reduction of TNFR2 expression alongside blood sinusoids in adult liver tissue and decrease TNFR2 expression in glomerulus, extracellular matrix, and tubules in adult kidney after exposure to GA3 (Seleem and Hussein, 2018). Also, TNF expression was decreased after arsenic exposure (Hermann and Kim, 2005). Clothianidin insecticide inhibits TNF- $\alpha$  expression (Di Prisco et al., 2017). The



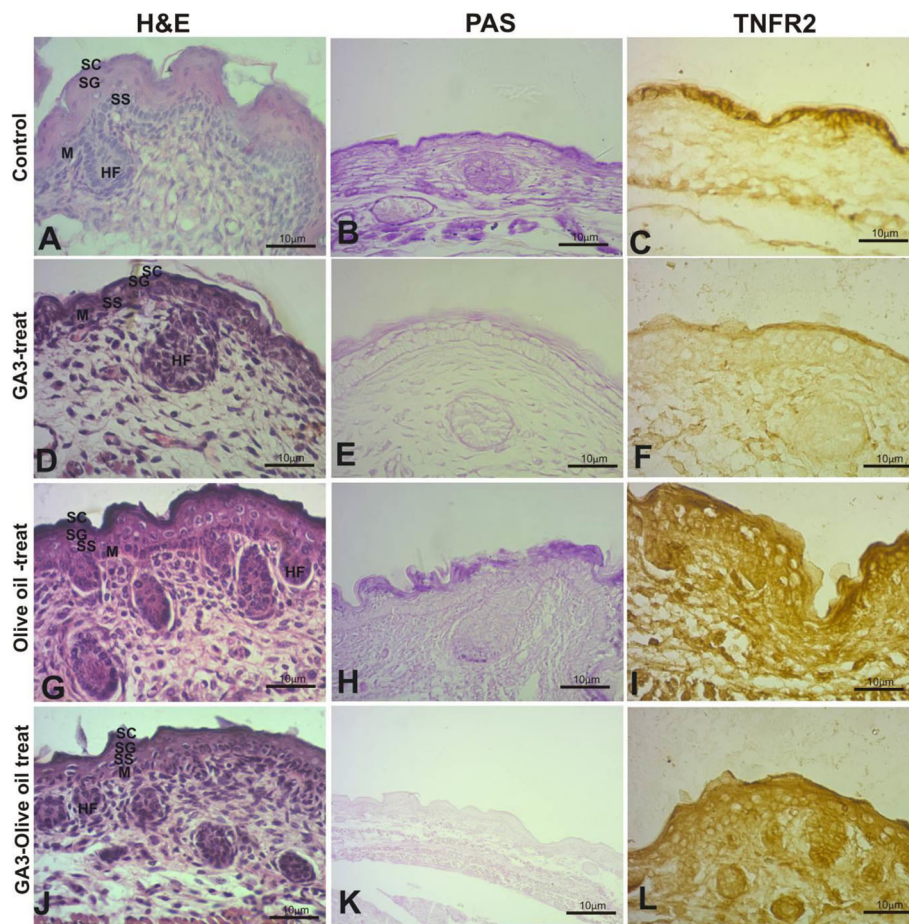
**Fig. 8** Photomicrographs of H&E-, PAS-, and TNFR2-stained sections of developing skin at E14. The skin consists of the epidermis (Ep), hair follicles primordium (FP), and dermis. The control skin showed positive carbohydrates in the basement membrane of the FP (**b**) and TNFR2 expression in the dermis (**c**). The skin of GA3-treated embryos showed a thin Ep with poor development of FP, decrease carbohydrate content, and downregulation of TNFR2 expression. The skin of olive oil-treated embryos showed similar structure to the control (**g**, **h**) but an increase of TNFR2 expression was observed (**i**). Improvement in the histopathological changes was noted in the skin of GA3-olive oil-treated embryos (**j–l**). Scale bar (**a–l**) = 10  $\mu$ m

reduction of TNF expression might be due to activation of death domain in TNFR causing apoptosis, whereas the receptors recruit procaspase-8 and procaspase-3 that mediate an apoptotic pathway in mammalian cells (Chang et al., 2003). The present study showed an increase in the expression of TNFR2 in the olive oil-treated group in the studied tissues. Our results were supported with previous observations in which the consumption of olive oil increased gene expression of some factors, e.g., brain-derived neurotrophic factor in the prefrontal cortex of rats (Zrelli et al., 2011; Ayissi et al., 2014). Also, administration of olive oil in pregnancy and breastfeeding may increase fibroblast growth factors (FGF-2) mRNA expression (Pase et al., 2015). Limited information is available about the effect of olive oil on TNFR2 and immune system. The maternal diet of olive oil can decrease the plasma pro-inflammatory cytokine

levels and regulates some growth factors (Shen et al., 2015; Pase et al., 2015) that may be attributed to the high contents of monounsaturated fatty acids in olive oil (Ayissi et al., 2014). The administration of olive oil exerts beneficial effects on the immune system (Puertollano et al., 2010) that may be attributed to oleic acid in olive oil components (Puertollano et al., 2007).

Many attempts have been carried out to counteract the toxicity of GA3 as using phycocyanin, pomegranate peel extracts, and grape seeds proanthocyanidin extract, terbium gibberellic complex by their ability as a scavenger of oxygen radicals or antioxidant properties (Hussein et al., 2015; Seleem and Hussein, 2018; Khalaf et al., 2019). In the same context, previous studies which administered *Nigella sativa* oil, silymarin, and vitamin C to reduce the histopathological alteration induced by GA3 during rat embryogenesis were conducted (Ali





**Fig. 9** Photomicrographs of H&E-, PAS-, and TNFR2-stained sections of developing skin at E18. The control skin contains Malpighian (M), stratum spinosum (SS), stratum granulosum (SG), stratum corneum (SC), and a well-developed hair follicle (HF) (**a**). PAS- and TNFR2-stained skin sections revealed localization of carbohydrates and TNFR2 expression in the epidermis (**b**, **c**). The skin of GA3-treated embryos showed a thin wrinkled epidermis, a less abundant and disorganized hair follicles with shrinkage of dermal papilla and decrease in PAS and TNFR2 expression in the epidermis (**d–f**). The skin of olive oil-treated embryo showed H&E and PAS staining similar to control, but high TNFR2 expression (**i**). The skin of GA3-olive oil-treated embryos showed improvement in the histopathological changes (**j–l**). Scale bar (**a–l**) = 10  $\mu$ m

et al., 2018; Alsemeh et al., 2019). The current study used olive oil to counteract the GA3 toxicity that led to a marked improvement in the histopathological changes occurring in the developing liver, kidney, and skin. Olive oil was reported in protection of embryos and newborns during pregnancy and breastfeeding (Trapani et al., 2017). Olive oil consumption during pregnancy prevents wheezing in children, asthma development, and atopy in children (Chatzi and Kogevinas, 2009; Trapani et al., 2017). Also, oral administration and topical application of olive oil used in the treatment of wounds and burns of skin conditions in infants and neonates (Sakazaki et al., 2007; Kiechl-Kohlendorfer et al., 2008). Administration of pregnant women with healthy diet contain olive oil reduces risk postpartum depressive symptoms, protect their children from expected dangers, and influence the urinary metabolome of nursing mothers and the health of breastfed children (Chatzi et al., 2011; Silva

et al., 2015). Also, supplementation of olive oil is considered protective against hepatotoxicity induced in male Wistar rats and protects red blood cells from oxidative damage (Paiva-Martins et al., 2015; Kalaiselvan et al., 2016).

## Conclusion

The present study was conducted to evaluate the ameliorative effect of olive oil on GA3-induced embryonic defects during mice gestation. From the presented data, it is obvious that olive oil supplementation during pregnancy ameliorates the defects induced with GA3 at both histological and immunohistochemical levels of the developing liver, kidney, and skin. The study recommended to consider olive oil as a protective agent against the hazardous effects of plant regulators that are widely used and reach the developing embryos during intrauterine development.

## Abbreviations

TNFR2: Tumor necrosis factor receptor 2; GA3: Gibberellic acid; H&E: Hematoxylin and eosin-stain

## Acknowledgements

Thanks a lot for the Zoology Department, Faculty of Science, Sohag University, Egypt.

## Authors' contributions

All authors participated in suggestion point, interpretation of results, and discussion. The authors read and approved the final manuscript.

## Funding

There is no funding for this work.

## Availability of data and materials

The data analyzed during the current study is available from the corresponding author.

## Ethics approval and consent to participate

The ethics approval of this study was carried out according to the guidance of ARRIVE guidelines and the Institute of Laboratory Animal Resources.

## Consent for publication

Not applicable.

## Competing interests

The authors declare that they have no competing interests.

Received: 26 January 2020 Accepted: 26 June 2020

Published online: 08 July 2020

## References

- Abdel Rahm, M. A., Abdel Atty, Y. H., Abdel Rahman, M. M., & Sabry, M. (2017). Structural changes induced by gibberellic acid in the renal cortex of adult male albino rats. *MOJ. Anat & Physiol*, 3(1), 21–27.
- Ali, M. H. M., Nasr El-Din, W. A., & Anter, S. (2018). Possible ameliorative effect of vitamin C on cerebellar toxicity induced by gibberellic acid during late pregnancy and early postnatal periods in albino rats. *Eur. J. Anat*, 22(4), 345–354.
- Alsemeh, A. E.; Moawad, R. S.; Abdelfattah, E. R. (2019). Histological and biochemical changes induced by gibberellic acid in the livers of pregnant albino rats and their offspring: Ameliorative effect of Nigella sativa. *Anat Sci Int*. 1–17.
- Ayissi, V., Ebrahimi, A., & Schluesener, H. (2014). Epigenetic effects of natural polyphenols: A focus on SIRT1-mediated mechanisms. *Mol. Nutr. Food Res*, 58(1), 22–32.
- Bermudez, B., Lopez, S., Ortega, A., Varela, L. M., Pacheco, Y. M., Abia, R., & Muriana, F. (2011). Oleic acid in olive oil: From a metabolic framework toward a clinical perspective. *Curr. Pharm. Des.*, 17, 831–843.
- Boğa, A., Binokay, S., & Sertdemir, Y. (2009). The toxicity and teratogenicity of gibberellic acid (GA3) based on the frog embryo teratogenesis assay-Xenopus (FETAX). *Turk J Biol*, 33, 181–188.
- Brun, J. P. (2000). The production of perfumes in antiquity: The cases of delos and paestum. *Am. J. Arch.*, 104, 277–308.
- Buchlowalow, B. I.; Bocker, W. (2010). *Imunohistochemistry. Basics and methods.* Springer Verlag Berlin Heidelberg, PP: 48.
- Camargo, A., Rangel-Zuniga, O. A., Haro, C., Meza-Miranda, E. R., Pena-Orihuela, P., Meneses, M. E., ... Perez-Jimenez, F. (2014). Olive oil phenolic compounds decrease the postprandial inflammatory response by reducing postprandial plasma lipopolysaccharide levels. *Food Chem.*, 162, 161–171.
- Casas-Agustench, P.; Fernandes, F.S.; Tavares do Carmo, M.G.; Visioli, F.; Herrera, E.; Davalos, A. (2015). Consumption of distinct dietary lipids during early pregnancy differentially modulates the expression of microRNAs in mothers and offspring. *PLoS ONE*, 10: e0117858.
- Celik, I., & Tuluze, Y. (2006). Effects of indoleacetic acid and kinetin on lipid peroxidation and antioxidant defense in various tissues of rats. *Pestic Biochem Phys*, 84, 49–54.
- Chang, D. W., Xing, Z., Capacio, V. L., Peter, M. E., & Yang, X. (2003). Interdimer processing mechanism of procaspase-8 activation. *The EMBO Journal*, 22, 4132–4142.
- Chatzi, L., & Kogevinas, M. (2009). Prenatal and childhood Mediterranean diet and the development of asthma and allergies in children. *Public Health Nutr.*, 12, 1629–1634.
- Chatzi, L.; Melaki, V.; Sarri, K.; Apostolaki, I.; Roumeliotaki, T.; Georgiou, V.; Vassilaki, M.; Koutis, A.; Bitsios, P.; Kogevinas, M. (2011). Dietary patterns during pregnancy and the risk of postpartum depression: The mother-child 'Rhea' cohort in Crete, Greece. *Public Health Nutr.*, 14(9):1663-1670.
- Chen, Z., Jiang, H., Wan, Y., Bi, C., & Yuan, Y. (2012). H2O2-induced secretion of tumor necrosis factor-α evokes apoptosis of cardiac myocytes through reactive oxygen species dependent activation of p38 MAPK. *Cytotechnol.*, 64, 65–73.
- Covas, M. I. (2007). Olive oil and the cardiovascular system. *Pharmacological Research*, 55(3), 175–186.
- Crespo, M. C., Tomé-Carneiro, J., Dávalos, A., & Visioli, F. (2018). Pharma-nutritional properties of olive oil phenols. Transfer of New Findings to Human Nutrition. *Foods*, 7(6), 1–29.
- Di Prisco, G., Iannaccone, M., Ianniello, F., Ferrara, R., Caprio, E., Pennacchio, F., & Capparelli, R. (2017). The neonicotinoid insecticide Clothianidin adversely affects immune signaling in a human cell line. *Scientific reports*, 7(1), 13446.
- Drury, R. A. B., & Wallington, E. A. (1976). *Carleton's histological technique*. London: Oxford University Press.
- El-Mofly, M. M., Sakr, S. A., & Rizk, A. M. (1994). Carcinogenic effect of gibberellin A3 in Swiss albino mice. *Nutr. Cancer*, 21, 183–190.
- El-Sayyad, H. I., Abo Egl, M. H., Mortada, M. M., Ramadan, M. M., & Elbeeh, M. E. (2012). Evaluation of acute toxicity and teratogenic effects of some plant growth regulators on albino rat embryo. *J. Plant Prot. and Path. Mansura Univ. Vol.*, 3(9), 905–919.
- Escrib, E., Solanas, M., Moral, R., & Escrich, R. (2011). Modulatory effects and molecular mechanisms of olive oil and other dietary lipids in breast cancer. *Curr. Pharm. Des.*, 17, 813–830.
- Esposto, K.; Marfella, R.; Ciotola, M. Di Palo, C.; Giugliano, F.; Giugliano, G.; D'Armiento, M.; D'Andrea, F.; Giugliano, D. (2004). Effect of a Mediterranean-style diet on endothelial dysfunction and markers of vascular inflammation in the metabolic syndrome: A randomized trial. *JAMA*. 292(12):1440-1446.
- Figueiredo-González, M., Reboredo-Rodríguez, P., González-Barreiro, C., Simal-Gándara, J., Valentão, P., Carrasco-Pancorbo, A., ... Cancho-Grande, B. (2018). Evaluation of the neuroprotective and antidiabetic potential of phenolic extracts from virgin olive oils by in vitro assays. *Food Res Int.*, 106, 558–567.
- Gong, D., Geng, C., Jiang, L., Cao, J., Yoshimura, H., & Zhong, L. (2009). Effects of hydroxytyrosol-20 on carrageenan-induced acute inflammation and hyperalgesia in rats. *Phyto. Res.*, 23, 646–650.
- Halliwell, B., & Gutteridge, J. M. C. (1999). *Free radicals in biology and medicine*, (third ed, pp. 449–450). New York: Oxford University Press.
- Hermann, A. C., & Kim, C. H. (2005). Effects of arsenic on zebrafish innate immune system. *Marine Biotechnology*, 7(5), 494–505.
- Hussein, M. M. A., Ali, H. A., & Ahmed, M. M. (2015). Ameliorative effects of phycocyanin against gibberellic acid induced hepatotoxicity. *Pestic Biochemistry and Physiology*, 119, 28–32.
- ILAR (Institute of Laboratory Animal Resources) (US). Committee on Care & Use of Laboratory Animals. (1986). Guide for the care and use of laboratory animals (No. 86). US Department of Health and Human Services, Public Health Service, National Institutes of Health.
- Incari, A., Serra, G., Atzeri, A., Melis, M. P., Serrelli, G., Bandino, G., ... Deiana, M. (2016). Extra virgin olive oil phenolic extracts counteract the pro-oxidant effect of dietary oxidized lipids in human intestinal cells. *Food Chem. Toxicol.*, 90, 171–180.
- Kalaiselvan, I., Samuthirapandi, M., Govindaraju, A., Sheeja Malar, D., & Kasi, P. D. (2016). Olive oil and its phenolic compounds (hydroxytyrosol and tyrosol) ameliorated TCDD-induced hepatotoxicity in rats via inhibition of oxidative stress and apoptosis. *Pharm. Biol.*, 54, 338–346.
- Khalaf, H. A., Arafat, E. A., & Ghoneim, F. M. (2019). A histological, immunohistochemical and biochemical study of the effects of pomegranate peel extracts on gibberellic acid induced oxidative stress in adult rat testes. *Biotechnic Histochem*, 30, 1–14.
- Kiechl-Kohlendorfer, U., Berger, C., & Inzinger, R. (2008). The effect of daily treatment with an olive oil/lanolin emollient on skin integrity in preterm infants: A randomized controlled trial. *Pediatric Derm.*, 25, 174–178.
- Kilkenny, C., Browne, W. J., Cuthill, I. C., Emerson, M., & Altman, D. G. (2010). The ARRIVE guidelines animal research: Reporting in vivo experiments. *PLoS Biol*, 8(6), e1000412.
- Kok, F. J.; Kromhout, D. (2004). Atherosclerosis: Epidemiological studies on the health effects of a Mediterranean diet. *European Journal of Nutrition*, 43(1):1/2-1/5.



- Lamfon, H. A. (2013). Gibberellin A3 induced ovarian toxicity and oxidative stress in albino rat. *Archives Des Sciences*, 66(3), 148–155.
- Luceri, C., Bigagli, E., Pitozzi, V., & Giovannelli, L. (2017). A nutrigenomics approach for the study of anti-aging interventions: Olive oil phenols and the modulation of gene and microRNA expression profiles in mouse brain. *Eur. J. Nutr.*, 56, 865–877.
- Menendez, J. A., & Lupu, R. (2006). Mediterranean dietary traditions for the molecular treatment of human cancer: Anti-oncogenic actions of the main olive oil's monounsaturated fatty acid oleic acid (18:1n-9). *Curr. Pharm. Biotech.*, 7, 495–502.
- Omar, S. H. (2010). Oleuropein in olive and its pharmacological effects. *Sci. Pharm.*, 78, 133–154.
- Ozmen, M., Topcuoglu, S. F., Bozcuk, S., & Bozcuk, N. A. (1995). Effects of abscisic acid and gibberellic acid on sexual differentiation and some physiological parameters of laboratory mice. *Turk. J. Biol.*, 19, 357–364.
- Paiva-Martins, F., Gonçalves, P., Borges, J. E., Przybylska, D., Ibba, F., Fernandes, J., & Santos-Silva, A. (2015). Effects of the olive oil phenol metabolite 3,4-dhpeadad2 on human erythrocyte oxidative damage. *Food Funct.*, 6, 2350–2356.
- Parkinson, L., & Keast, R. (2014). Oleocanthal, a phenolic derived from virgin olive oil: A review of the beneficial effects on inflammatory disease. *Intern. J. Mol. Sci.*, 15(7), 12323–12334.
- Pase, C. S., Teixeira, A. M., Roversi, K., Dias, V. T., Calabrese, F., Molteni, R., ... Burger, M. E. (2015). Olive oil-enriched diet reduces brain oxidative damages and ameliorates neurotrophic factor gene expression in different life stages of rats. *J Nutr Biochem.*, 26(11), 1200–1207.
- Pelucchi, C., Bosetti, C., Negri, E., Lipworth, L., & la Vecchia, C. (2011). Olive oil and cancer risk: An update of epidemiological findings through 2010. *Current Pharmaceutical Design*, 17(8), 805–812.
- Pitozzi, V., Jacomelli, M., Catelan, D., Servili, M., Taticchi, A., Biggeri, A., ... Giovannelli, L. (2012). Long-term dietary extra-virgin olive oil rich in polyphenols reverses age-related dysfunctions in motor coordination and contextual memory in mice: Role of oxidative stress. *Rejuven. Res.*, 15, 601–612.
- Puertollano, M. A., Puertollano, E., Alvarez, de Cienfuegos, G., de Pablo Martínez, M. A. (2010). Olive oil, immune system and infection. *Nutr Hosp.* 25(1):1-8.
- Puertollano, M. A., Puertollano, E., de Cienfuegos, G. A., & de Pablo, M. A. (2007). Significance of olive oil in the host immune resistance to infection. *British Journal of Nutrition*, 98(S1), S54–S58.
- Rabiei, Z., Bigdeli, M. R., & Rasoulian, B. (2013). Neuroprotection of dietary virgin olive oil on brain lipidomics during stroke. *Curr. Neurovasc. Res.*, 10, 231–237.
- Ramadan, M. F., & Moersel, J. T. (2006). Screening of the antiradical action of vegetable oils. *J. Food Compos. Anal.*, 19, 838–842.
- Rangaswamy, V. (2012). Improved production of gibberellic acid by *Fusarium moniliforme*. *J. Microbiol. Res.*, 2(3), 51–55.
- Rios-Irbe, E. Y., Flores-Cotera, L. B., Chavira, M. M., Gonzalez-Alatorre, G., & Escamilla-Silva, E. M. (2011). Inductive effect produced by a mixture of carbon source in the production of gibberellic acid by *Gibberella fujikuroi*. *World J. Microbiol. Biotechnol.*, 27(6), 1499–1505.
- Rosignoli, P., Fuccelli, R., Sepporta, M. V., & Fabiani, R. (2016). In vitro chemopreventive activities of hydroxytyrosol: The main phenolic compound present in extra-virgin olive oil. *Food Funct.*, 7, 301–307.
- Rosillo, M. A., Alcaraz, M. J., Sánchez-Hidalgo, M., Fernández-Bolaños, J. G., Alarcón-de-la-Lastra, C., & Ferrándiz, M. L. (2014). Anti-inflammatory and joint protective effects of extra-virgin olive oil polyphenol extract in experimental arthritis. *J Nutr. Biochem.*, 25(12), 1275–1281.
- Ruiz-Canela, M., & Martínez-González, M. A. (2011). Olive oil in the primary prevention of cardiovascular disease. *Maturitas*, 68(3), 245–250.
- Sakazaki, F., Kataoka, H., Okuno, T., Ueno, H., Semma, M., Ichikawa, A., & Nakamura, K. (2007). Ozonated olive oil enhances the growth of granulation tissue in a mouse model of pressure ulcer. *Ozone: Sci. Eng.*, 29, 503–507.
- Schwechheimer, C., & Willige, B. C. (2009). Shedding light on gibberellic acid signaling. *Curr. Opin. Plant Biol.*, 12, 57–62.
- Scoditti, E., Calabrese, N., Massaro, M., Pellegrino, M., Storelli, C., Martines, G., ... Carluccio, M. A. (2012). Mediterranean diet polyphenols reduce inflammatory angiogenesis through MMP-9 and COX-2 inhibition in human vascular endothelial cells: A potentially protective mechanism in atherosclerotic vascular disease and cancer. *Arch. Biochem. and Biophys.*, 527, 81–89.
- Seleem, A. A. (2019). Teratogenicity and neurotoxicity effects induced by methomyl insecticide on the developmental stages of *Bufo arabicus*. *Neurotoxicology and teratology*, 72, 1–9.
- Seleem, A. A., & Hussein, B. H. M. (2018). Synthesis and effect of a new Terbium gibberellic complex on the histopathological alteration induced by Gibberellic acid on liver and kidney of mice *Mus musculus*. *Chem Biol Drug Des.*, 92, 1288–1300.
- Sharma, S., & Agarwal, R. K. (2004). Butachlor induced changes in tissue glycogen of the fish, *Heteropneustes fossilis*. *J. Bionotes.*, 6(2), 52.
- Shen, Y., Wan, H., Zhu, J., Fang, Z., Che, L., Xu, S., ... Wu, D. (2015). Fish oil and olive oil supplementation in late pregnancy and lactation differentially affect oxidative stress and inflammation in sows and piglets. *Lipids.*, 50(7), 647–658.
- Silva, S., Combet, E., Figueira, M., Koeck, T., Mullen, W., & Bronze, M. (2015). New perspectives on bioactivity of olive oil: Evidence from animal models, human interventions and the use of urinary proteomic biomarkers. *Proc Nutr Soc.*, 74(3), 268–281.
- Silva, S., Sepodes, B., Rocha, J., Direito, R., Fernandes, A., Brites, D., ... Figueira, M. E. (2015). Protective effects of hydroxytyrosol-supplemented refined olive oil in animal models of acute inflammation and rheumatoid arthritis. *J Nutr. Biochem.*, 26(4), 360–368.
- Stadtman, E. R., & Levine, R. L. (2000). Protein oxidation, reactive oxygen species. *From radiation to molecular biology*. *Ann. N. Y. Acad. Sci.*, 899, 191–208.
- Tomlin, C. D. (2004). Gibberellic acid (77-06-5). In: *The e-pesticide manual*, 13th ed., vol 3. Surrey UK, British Crop. Protection council.
- Trapani, G., Vagliano, L., Giribaldi, M., Cavallarin, L., & Coscia, A. (2017). Olive oil: Maternal and pediatric health. *Journal of Pediatric and Neonatal Individualized Medicine.*, 6(1), e060133.
- Troudi, A., Ben, A. I., Soudani, N., Samet, A. M., & Zeghal, N. (2011). Oxidative stress induced by gibberellic acid on kidney tissue of female rats and their progeny: Biochemical and histopathological studies. *J. Physiol. Biochem.*, 67(3), 307–316.
- Troudi, A., Bouaziz, H., Soudani, N., Ben Amara, I., Boudawara, T., Touzani, H., ... Zeghal, N. (2012). Neurotoxicity and oxidative stress induced by gibberellic acid in rats during late pregnancy and early postnatal periods: Biochemical and histological changes. *Experimental and Toxicologic Pathology Journal*, 6, 583–590.
- Troudi, A., Samet, A. M., & Zeghal, N. (2010). Hepatotoxicity induced by gibberellic acid in adult rats and their progeny. *Exp. Toxicol. Pathol.*, 62(6), 637–642.
- Visioli, F., & Galli, C. (2002). Biological properties of olive oil phytochemicals. *Crit. Rev. Food Sci. Nutr.*, 42(3), 209–221.
- Zbidi, H., Salido, S., Altarejos, J., Perez-Bonilla, M., Bartegi, A., Rosado, J. A., & Salido, G. M. (2009). Olive tree wood phenolic compounds with human platelet antiaggregant properties. *Blood Cells, Molecules and Diseases.*, 42, 279–285.
- Zrelli, H., Matsuoka, M., Kitazaki, S., Araki, M., Kusunoki, M., Zarrouk, M., & Miyazaki, H. (2011). Hydroxytyrosol induces proliferation and cytoprotection against oxidative injury in vascular endothelial cells: Role of Nrf2 activation and HO-1 induction. *J. agric. food chem.*, 59(9), 4473–4482.

## Publisher's Note

Springer Nature remains neutral with regard to jurisdictional claims in published maps and institutional affiliations.

**Submit your manuscript to a SpringerOpen<sup>®</sup> journal and benefit from:**

- Convenient online submission
- Rigorous peer review
- Open access: articles freely available online
- High visibility within the field
- Retaining the copyright to your article

Submit your next manuscript at ► [springeropen.com](https://www.springeropen.com)