Sharafeldein *et al.*
The Journal of Basic and Applied Zoology (2023) 84:25
https://doi.org/10.1186/s41936-023-00347-5

The Journal of Basic and Applied Zoology

RESEARCH

Open Access

The collagen enhancement by *Spirulina* extract in intrinsic and extrinsic skin aging in albino rat

Khaled Sharafeldein[1*], Hanan Ayesh[1], Safwatt Salama[2] and Azza M. Marei[1]

Abstract

Background The aging of the skin is considered a cumulative process that is classed as intrinsic or extrinsic. Environmental factors like sun exposure and air pollution are considered the main cause of extrinsic aging. Mainly, intrinsic aging reflects the genetic background and depends on time. Spirulina platensis unicellular blue–green algae have a variety of biological and nutritional activities because of their high level of nutrients. The current study aims to investigate the mechanism by which spirulina extract (SE) may act anti-aging in female albino rats. Spirulina extract (20 mg/mL) was injected subcutaneously before UVA irradiation (2.16 J/cm^2), daily for 7 days. The epidermal thickness and the collagen fibers layer were stained utilizing hematoxylin and eosin and Masson.

Results SE induced significant improvements in the activities of antioxidants including superoxide dismutase and reduced glutathione, down-regulating in expressions of inflammatory cytokines: interleukin-1β and tumor necrosis factor-α and reverses excessive ROS levels. As well as , the recovery of collagen density and reduction in the production of matrix metalloproteinases were presented.

Conclusions The results found that spirulina extract may delay the signs of skin aging by enhancing collagen as well as antioxidant activities and inhibiting collagen degradation and inflammation.

Keywords Collagen, Skin aging, Oxidation, *Spirulina*, Algae

Background

Skin is the largest organ in the body and acts as the first line of defense between the body's internal organs and the outside world. The skin acts as an immune organ to detect infections preventing infringements of pathogens, ultraviolet radiation (UVR), and mechanical, thermal and physical injury (Letsiou, 2021; Proksch et al., 2008). Therefore, caring for the skin is imperative to better health and not a luxury. There are two types of skin aging: intrinsic and extrinsic (Lee et al., 2020). Intrinsic aging is known as chronological aging and is defined as the natural aging process depending on normal biological processes. The intrinsic aging is influenced by the internal factors that include changes in gene expression, changes in the neuroendocrine system and the development of skin disorders disrupting the cutaneous barrier functions or skin involvement in connective tissue disorders (Sjerobabski-Masnec & Situm, 2010). Extrinsic aging, also known as photoaging, on the other hand, is a phenomenon that can be somewhat resisted. Our skin ages prematurely as a result of numerous extrinsic, or external, factors that frequently cooperate with natural aging. Exposure to (UVR) is the most detrimental factor for this reason (Krutmann et al., 2021). UVA radiation (400–320 nm) is about 95–98% of the total UV rays that reach the surface of the earth, as well as penetrate deeper

*Correspondence:
Khaled Sharafeldein
Khaled.sharafeldein@fsc.bu.edu.eg
[1] Department of Zoology, Faculty of Science, Benha University, Benha, Egypt
[2] Egyptian Atomic Energy Authority, National Center for Radiation Research and Technology, Cairo, Egypt

Springer Open

© The Author(s) 2023. **Open Access** This article is licensed under a Creative Commons Attribution 4.0 International License, which permits use, sharing, adaptation, distribution and reproduction in any medium or format, as long as you give appropriate credit to the original author(s) and the source, provide a link to the Creative Commons licence, and indicate if changes were made. The images or other third party material in this article are included in the article's Creative Commons licence, unless indicated otherwise in a credit line to the material. If material is not included in the article's Creative Commons licence and your intended use is not permitted by statutory regulation or exceeds the permitted use, you will need to obtain permission directly from the copyright holder. To view a copy of this licence, visit http://creativecommons.org/licenses/by/4.0/.

than UVB (290–320 nm), into the skin, inducing alterations of the dermal connective tissue. Therefore, UVA is considered the main culprit responsible for skin cancers and photoaging (Lephart, 2016). Yogianti et al. (2014) revealed that intense exposure to UV radiation is a risk factor for the development of skin cancers. Photoaged skin appears very dry, has coarse wrinkles and has telangiectasia and pigmentations, while intrinsic chronological aging is smooth, pale and dry, and has fine wrinkles. In general, skin aging appears as many atrophy-related symptoms, such as epidermal thinning and irregular collagen and elastic fibers (Kammeyer & Luiten, 2015). It is commonly acknowledged that the primary cause of intrinsic and extrinsic aging is the destruction of the antioxidant defense systems (SOD, CAT, GSH) and the accumulation of damage of reactive oxygen species (ROS) (Kammeyer & Luiten, 2015). In addition, the disturbed defense mechanism includes antioxidant molecules such as vitamins A, C and E, leading to the accumulation of damage of reactive oxygen species (ROS) (Poljšak et al., 2012). Excess ROS activates extracellular matrix (ECM) remodeling proteins including matrix metalloproteinases (MMPs) such as MMP-1, MMP-3 and MMP-9. MMP-1 mainly initiates directly collagen breakdown that is considered one of the most important factors affecting skin aging (Pittayapruek et al., 2016; Shin et al., 2019). There is a great demand for natural products to delay the effects of skin aging (Duan et al., 2021; Rincón-Fontán et al., 2020). *Spirulina* (*Arthrospira platensis*) is unicellular blue–green algae that belongs to the cyanobacteria group. *Spirulina* strongly induces antioxidant enzyme activity, helps to prevent lipid peroxidation and DNA damage, and scavenges free radicals (Wu et al., 2016). *Spirulina* also exerts a variety of immunomodulatory and anti-inflammatory activities by regulating key cytokines, including interleukin (IL)-1β, IL-2, IL-4, IL-6, IL-10 and tumor necrosis factor (TNF)-α (Wu et al., 2016). There are many components in *Spirulina* including, several minerals, proteins, essential fatty acids, polysaccharides, pigments, including β-carotene, vitamins, antioxidants, a large number of peptides, amino acids and immunologically effective compounds (Amer, 2018; Mendiola et al., 2007; Ovando et al., 2018). These components make *Spirulina* extract (SE) a potential pharmaceutical for cosmetic product developments and basically for skin disease resistance. The target of this study is to assess the influence of intrinsic and extrinsic factors on aging and their resistance by *Spirulina* extract.

Methods

Algal extract

Spirulina algal extract was purchased from Aim Grow Biotech Co., Ltd, China, as a dark green powder that contains 67.97% dry weight proteins, β-carotene (120 mg/100 g), 6% lipids and 10.5% phycocyanin.

Skin photoaging model and treatment

UVA lamp (F15T8/BL, Hitachi, Japan) 15W was used for UV irradiation. To achieve a UVA spectral radiance of 300 μW/cm^2, the distance between the lamp and the rats was 20 cm. The dorsal hair of all rats was removed with a shaver within an area of 2.5–3 cm^2 and exposed to radiation daily for 2 h/day in one session for a week, with daily dose of 2.16 J/cm^2. Animals of irradiated groups were taken the doses equally as one group. A UV radiometer (TM 208, Tenmars, Taiwan) was used to measure the lamp's radiation output as described by Prasedya et al. (2019).

Treatment

Spirulina extract (SE) was weighed and dissolved in 9% normal saline. A total of 200 μL of extract and vehicle (saline) were injected subcutaneously into the shaved dorsal skin for respective treatment groups at a daily dose of (20 mg/mL), and SE was injected 1 h before irradiation.

The animals and the design of the experiment

A number of 42 (*Rattus norvegicus*) female albino rats were used in the present study divided by age into 28 young females (6–8 weeks old) weighing 120–180 g and 14 old females (20–22 months old) weighing 250–300 g. The animals of the study were obtained from the National Center for Radiation Research and Technology, Cairo, Egypt. The protocol for conducting the acute and in vivo studies was performed according to the guidelines of the care and use of laboratory animals (8th edition), and the study was approved by the Institutional Ethics Committee for animal care and use (ZD/FSc/BU-IACUC/2022-13) of the Faculty of Science, Benha University, Egypt. Animals were adapted for 1 week and were kept in metal cages in a well-ventilated space. All experiments were performed in accordance with relevant named guidelines and regulations. The authors complied with the ARRIVE guidelines. Rats were allotted into 6 groups (7 animals each) as follows:

The extrinsic experiment

Group I (GI) control young rats were (only subjected to shaving).

Group II (GII) young rats received SE (20 mg/mL) daily for a week.

Group III (GIII) young rats were administered a daily dose of saline and an hour later exposed to UVR (2.16 J/cm^2), daily for a week.

Group IV (GIV) young rats received SE (20 mg/ml) and an hour later exposed to UVR (2.16 J/cm^2), daily for a week.

The intrinsic experiment

Group V (GV) control old rats were (only subjected to shaving), considering (GI) as a young control.

Group VI (GVI) old rats received SE (20 mg/ml) daily for a week.

Histopathological study

Forty-eight hours after the last irradiation, animals of each group were euthanized by over dose of sodium pentobarbital. Samples of hairless skin were obtained from the rats' backs, which were then sliced into quarter-inch strips and soaked in 10% buffered formalin for routine histology study. Slices were pigmented with hematoxylin and eosin stain (H&E) to investigate the thickness of the epidermis and Masson's trichrome stain to investigate the collagen fibers' density. Collagen is stained blue–green, while cytoplasm, red blood cells and nuclei are stained red. Stained images were investigated and captured using a light microscope (Bio-Med, Japan) with a digital camera (RAS-312, LAINSY Co., Egypt). The observations of skin slides were done by Omer Ghoneimy, Associate Prof of Histology, Benha University, and revised by Seham Ahmed, Professor of Histology, Benha University.

Homogenization

Skin tissue samples were homogenized in phosphate-buffered saline (PBS) as previously described by Takach (2013) using Laboratory Homogenizer (GLH 850, Omni International, USA).

Immunological study

The level of reactive oxygen species (ROS) was evaluated in the homogenate skin colorimetrically using a colorimetric kit (Biodiagnostic Company, Giza, Egypt) according to Koracevic et al., (2001). The activities of superoxide dismutase (SOD) were measured according to Nishikimi et al., (1972), using Biodiagnostic kits (Giza, Egypt). Reduced glutathione (GSH) was measured as a previously described by Beutler et al. (1963), using Biodiagnostic kits (Giza, Egypt). Interleukin-1β (IL-1β) and tumor necrosis factor-α (TNF-α) were evaluated using enzyme-linked immunosorbent assay (ELISA) kits (Elabscience Company, USA) following the manufacturer's protocol using a multi-mode microplate reader (BMG Labtec, Manchester, UK) at 450 nm.

Physiological study (collagen biosynthesis)

The activity of hydroxyproline (Hyp) levels was evaluated in skin homogenate according to (Kesava Reddy & Enwemeka, 1996), while skin matrix metalloproteinase-1 (MMP-1) was measured using a commercial ELISA kit (Elabscience Company, USA) following the manufacturer's protocol.

Statistical analysis

The values of measured and studied parameters were expressed by the mean of 7 individual values (M) ± standard deviation (SD) and correlation analysis to assess the strength of association between two variables by using the SPSS (version 25) program produced by IBM Software, Inc. (Chicago, USA). One-way analysis of variance (ANOVA) was used for statistical analysis, followed by Duncan's test as a post hoc test (Duncan, 1957). A p value was considered significant if $p < 0.05$.

Results

Histopathological study

Hairless rat morphology

Skin backs of control and *Spirulina* extract-treated groups appeared relaxed, with no wrinkles or inflammation (Fig. 1A, B). UVA-irradiated rats showed distinct features: dark brown color, deep wrinkles and acutely inflamed surface (Fig. 1C). After treatment, the UVA-irradiated group was treated with SE, and the appearance of the skin was greatly improved as relaxed surface with mild wrinkles, recovered inflammation and wound healing (Fig. 1D). The skin of the old rats showed irregular epidermal thickening with fine wrinkles (Fig. 1E). The old-aged rats treated with SE had a greatly improved skin when compared with control rats (Fig. 1A, F).

Epidermal thickness

Hematoxylin and eosin (H&E) staining showed increased epidermal thickness (hyperplasia) and the formation of deep wrinkles in the UVA-irradiated group (GIII) compared with control (GI) (Fig. 2A). Irradiated rats also showed atrophy of the sebaceous gland and thickening of the wall of blood vessels. SE-administrated group (GIV) showed abundant photoprotective activity and retained an intact epidermal layer of the skin (Fig. 2A). On the other hand, decreased atrophy of the epidermis and relative improvement in skin wrinkle formation of the old treated group (GVI) were observed compared with control old rats (GV), which showed remarkable wrinkle formation, epidermal thickening and desquamation compared with control young (GI) (Fig. 2B).

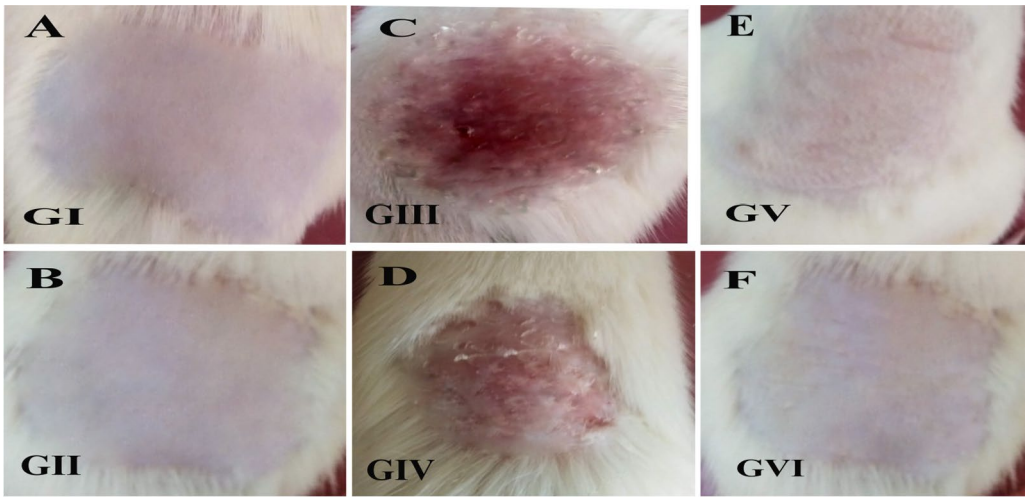

Fig. 1 Morphology of the albino rat shaved skin. **A** GI-control group, **B** GII-SE, **C** GIII-UVA group, **D** GIV-UVA + SE group, **E** GV-old untreated group and **F** GVI-old + SE group

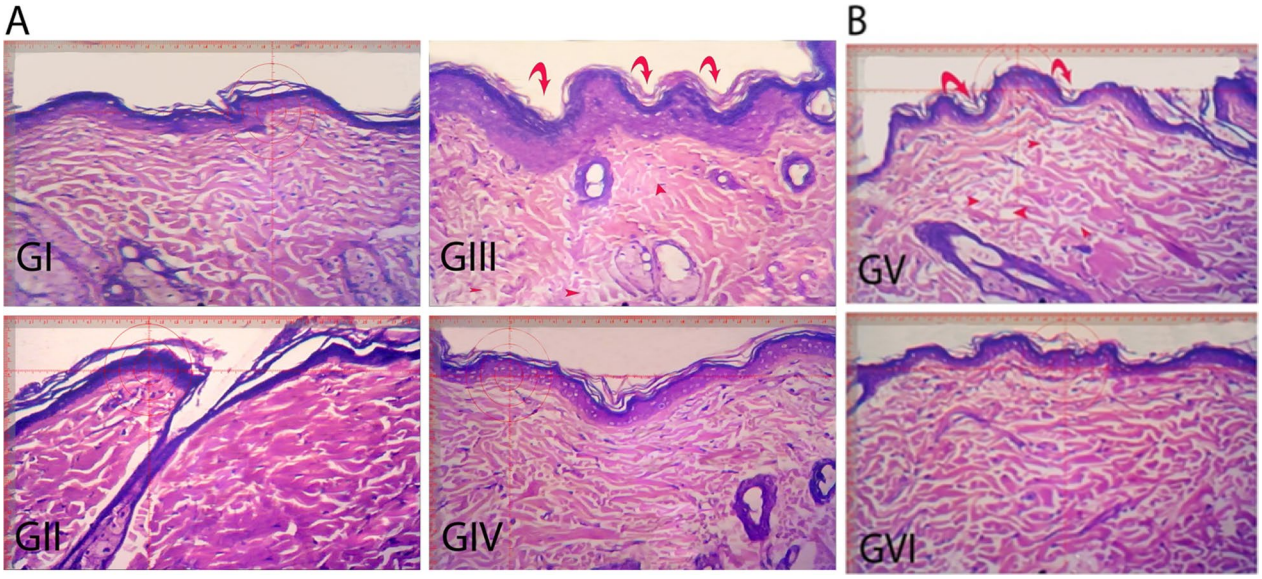

Fig. 2 Effect of *Spirulina* extract on the histological appearance of the albino rat skin (HE stains 10×). GI: control young group, GII: SE only group, GIII: UVA group, GIV: UVA + SE group, GV: old untreated group and GVI-old + SE group, arrows: wrinkles, arrowheads: destruction

Dermal collagen fiber

Using Masson's trichrome stain, the effect of SE administration on dermal collagen fibers in the dorsal skin was assessed. In the control group (GI), collagen fibers with blue dye were abundantly found in the dermis of the dorsal skin (Fig. 3A). However, in the UVA group (GIII), collagen was apparently destructed with follicular atrophy (Fig. 3A). In contrast, UVA with SE received group (GIV) showed amelioration of the reduced collagen fibers compared to the UVA group (pale color). There was manifested clear inflammatory infiltration and hemorrhage in the whole dermis in the UVA group (GIII) compared with the other groups; however, the UVA + SE received group (GIV) showed a noticeable recovery (Fig. 3A). The intrinsic aging showed no great change of collagen layer in old groups, except little destruction in the group (GV) compared to the young control group (GI) (Fig. 3B).

Immunological study

When compared to both the control group (GI) and the UVA + SE-treated group (GIV), the levels of ROS in the UVA group (GIII) significantly increased, as indicated

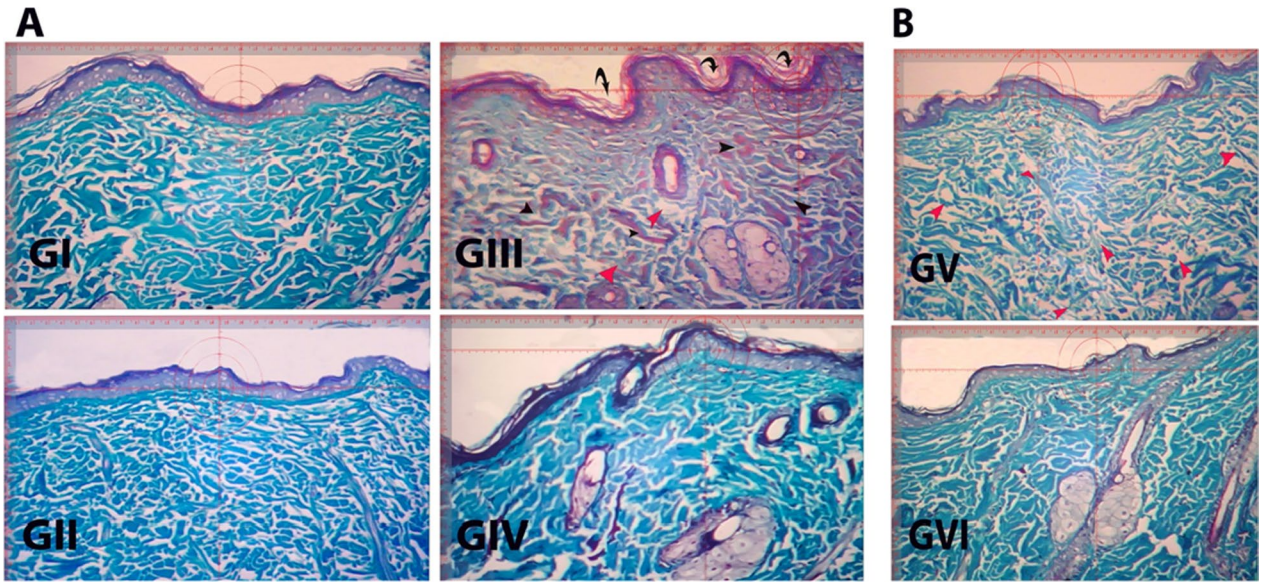

Fig. 3 Effect of SE on the collagen fiber of the albino rat skin (Masson stain 10×).GI: control young group, GII: SE only group, GIII: UVA group, GIV: UVA + SE, GV: old untreated group and GVI: old + SE group, red arrowheads: distraction, black arrowheads: hemorrhage, arrows: wrinkles

in (Table 1, Fig. 4). Additionally, the levels of ROS in SE-treated old rats (GVI) were significantly decreased compared with the control old rats (GV) ($p < 0.05$) and eventually returned to the levels of control young rats (GI). Additionally, compared with the control group and UVA + SE received group (GIV) the UVA irradiation group (GIII) showed a significant decline in SOD activities and GSH levels ($p < 0.05$). The same results were shown in the old control rats (GV) when compared with the old group who received SE (GVI) and the control young group (GI) ($p < 0.05$). On the other hand, there was a significant excess in the TNF-α and IL-1β levels of the UVA-irradiated group (GIII) group when compared with both control group and UVA + SE-treated group (GIV) ($p < 0.05$). Prominently, SE suppressed the (TNF-α and IL-1β) levels and restored them to control levels. The same results were represented in the group of control old rats (GV) when compared with the old treated group (GVI) and control young group (GI) ($p < 0.05$) (Table 1).

Physiological study (collagen biosynthesis)

As shown in Table 1, Fig. 5A, the levels of Hyp were significantly decreased in the UVA-irradiated group (GIII) compared to the control group (GI) ($P < 0.05$). Meanwhile, compared to the UVA-irradiated group and the control old group, young and old rats administered SE (GII, GVI) exhibited significantly higher levels of Hyp ($P < 0.05$). The MMP-1 content of skin tissue homogenate increased

Table 1 Effects of *Spirulina* extract (SE) on the biochemical markers of skin tissue

	GI	GII	GIII	GIV	GV	GVI
ROS	0.175 ± 0.017^{ab}	0.170 ± 0.007^{b}	0.214 ± 0.003^{c}	0.193 ± 0.013^{a}	0.202 ± 0.016^{c}	0.169 ± 0.019^{b}
SOD	0.545 ± 0.020^{a}	0.539 ± 0.011^{a}	0.382 ± 0.048^{b}	0.482 ± 0.012^{c}	0.502 ± 0.044^{c}	0.541 ± 0.20^{a}
GSH	22.406 ± 0.947^{a}	21.264 ± 1.841^{a}	15.880 ± 1.548^{b}	22.20 ± 1.358^{a}	15.954 ± 1.914^{b}	20.686 ± 1.555^{a}
TNF	24.256 ± 7.801^{a}	21.486 ± 6.576^{a}	33.278 ± 7.320^{b}	22.628 ± 4.490^{a}	36.258 ± 6.637^{b}	17.096 ± 3.540^{a}
IL-1	8.400 ± 1.908^{a}	$0.7.408 \pm 1.050^{acd}$	13.972 ± 3.554^{b}	9.256 ± 2.144^{a}	7.780 ± 1.068^{ac}	7.122 ± 1.1148^{d}
Hyp	99.60 ± 2.61^{a}	119.72 ± 10.63^{a}	98.44 ± 2.31^{b}	$115.84 \pm 4.90b^{ad}$	119.20 ± 6.18^{b}	109.42 ± 1.33^{d}
MMP-1	1.31 ± 0.06^{a}	1.06 ± 0.03^{a}	1.46 ± 0.20^{b}	1.11 ± 0.04^{a}	1.08 ± 0.02^{c}	1.16 ± 0.06^{a}

Data are presented as means ± standard deviations ($n = 7$). In the same raw, values with similar letters mean a nonsignificant difference, and values with different letters mean a significant difference. GI (Group I): control young rats, GI (Group II): young rats received SE (20 mg/ml), GIII (Group III): young rats were administered a daily dose of saline and an hour later exposed to UVR (2.16 J/cm^2), GIV (Group IV): young rats received SE (20 mg/ml) and an hour later exposed to UVR (2.16 J/cm^2), GV (Group V): control old rats, GVI (Group VI): old rats received SE (20 mg/ml)

ROS reactive oxygen species level, *SOD* the activities of superoxide dismutase, *GSH* reduced glutathione, *IL-1β* interleukin-1β, *TNF-α* tumor necrosis factor-α, *Hyp* the activity of hydroxyproline, *MMP-1* matrix metalloproteinase-1

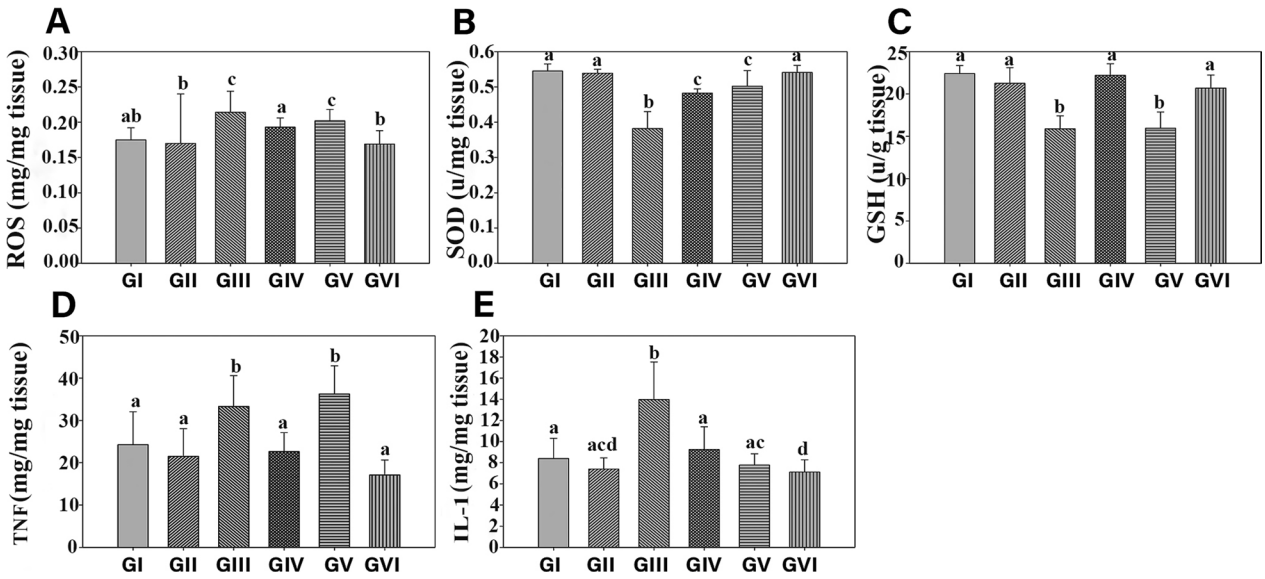

Fig. 4 Impression level of ROS, SOD, GSH, TNF and IL-1 in different experimented groups.GI: control young group, GII: SE only group, GIII: UVA group, GIV: UVA + SE, GV: old untreated group and GVI: old + SE group. Values with similar letters mean a non-significant difference, and values with different letters mean a significant difference

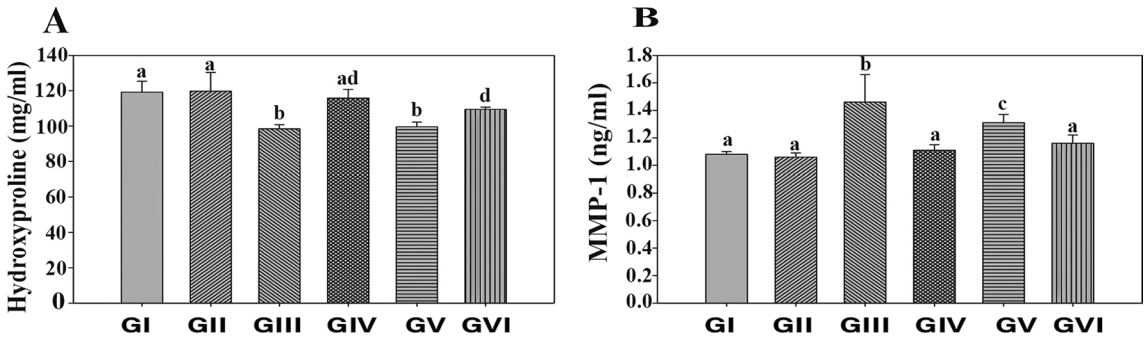

Fig. 5 Behavior of Hyp (**A**) and MMP-1 (**B**) in different experimented groups.GI: control young group, GII: SE only group, GIII: UVA group, GIV: UVA + SE, GV: old untreated group and GVI: old + SE group. Values with similar letters mean a non-significant difference, and values with different letters mean a significant differece

significantly in the UVA group (GIII) when compared with the control group (GI) while decreasing significantly in the UVA + SE group (GIV) (Table 1, Fig. 5B). Dramatically reduced levels of MMP-1 in old rats treated with SE (GVI) than in the old untreated group (GV) returned to levels of control young rats (GI) ($P < 0.05$).

Correlation analysis

Correlation analysis determines how strongly two quantitative variables are associated. The correlation coefficient (r) describes how one variable moves in relation to another. Its values can range from −1 to 1. When the points are near the line of best fit, r > 0.5 or −0.5 denotes a strong correlation. The strongest relationships between the biomarkers that were found in our investigation, which were represented by ROS, TNF-α and MMP-1, deserve special attention (Fig. 6A, B). SOD showed a significant negative correlation with IL1β and MMP-1 (Fig. 6C, G). Significant negative correlation between GSH and TNF-α was demonstrated (Fig. 6E). Hyp showed a significant negative correlation with MMP-1 (Fig. 6F).

Discussion

Skin is considered the first immune barrier to prevent infection and invading foreign organisms. Aging is associated with wrinkles, a thinning of the skin, loss of elasticity, delayed wound healing and dryness (Lephart,

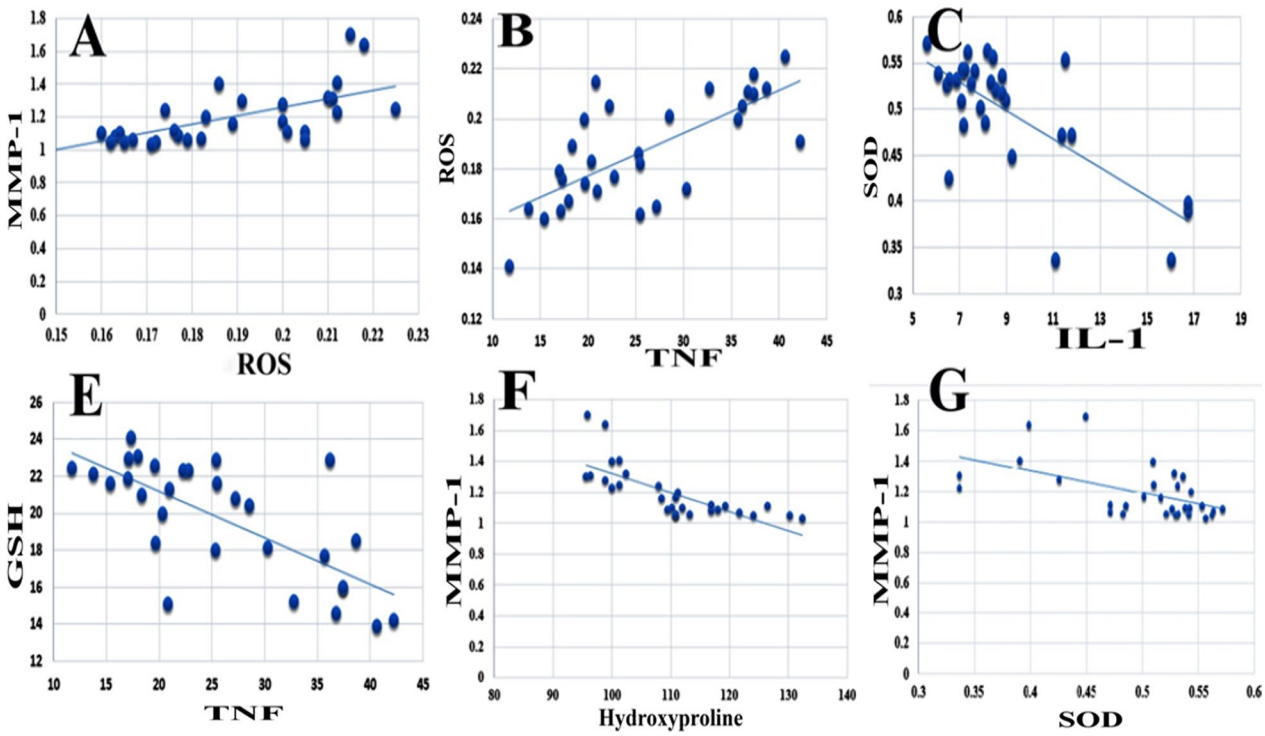

Fig. 6 Correlations strength among variable biomarkers in different experimented groups, strong correlation; when $r > 0.5$ or $<$ than -0.5

2016). There is a demand for the identification of novel sustainable raw materials and active compounds with moisturizing and wrinkle reduction properties for a youthful appearance. Recently, studies on the anti-aging impacts of algae, such as *Spirulina*, have received great interest (Pereira, 2018). There were no toxic impacts in many species of *Spirulina* on different organs by using acute or chronic doses (Kulshreshtha et al., 2008). According to our results, the use of the extract of *Spirulina* could suppress defects of skin aging due to its anti-inflammatory and antioxidant properties (Wu et al., 2016). The current study found that both types of aging induce the production of ROS. This may deteriorate the antioxidant defense system and disturb the redox balance, resulting in oxidative stress, which is supported by previous studies (Poljšak et al., 2012; Wang et al., 2016). Although there are antioxidant systems in the skin, the high level of ROS induced by aging exceeds their capacity. However, we found the activity of SOD and levels of GSH were improved in irradiated and the old rat groups with SE treatment. These radical-scavenging and antioxidant properties of SE may be mainly due to its phycocyanin content (10.5%) which is *Spirulina* major antioxidant component as determined by its action against H_2O_2 and generated OH radicals. Phycocyanin had shown wound healing, antimicrobial and anti-inflammatory properties (Grover et al., 2021). *Spirulina* contains additional vitamins and minerals in addition to the antioxidant and anti-inflammatory effects of β-Carotene (120 mg/100 g) (Wu et al., 2016). Skin inflammation is known to be caused by an imbalance between the production of ROS and the antioxidant defense system throughout complex pathways (D'Orazio et al., 2013). ROS activates mitogen-activated protein kinase (MAPK) which in turn activates nuclear factor (NF)-κB and activator protein-1 (AP-1), which leads to the release of inflammatory cytokines such as TNF-α and IL-1β (Campanini et al., 2013; Wang et al., 2016). These inflammatory cytokines stimulate the growth of keratinocytes in the epidermis and lead to hyperplasia of the epidermal cells as shown in the UVA group, as observed by Pillai et al. (2005). Similar to previous research, in the current study, the contents of IL-1β and TNF-α were significantly increased following UV exposure. However, after administration of SE, IL-1β and TNF-α contents were remarkably reduced to approximately the control level. Our results showed that after UV irradiation, the epidermal thickness was dramatically increased and the collagen fiber bundles were degraded and tangled. The abnormal histological alterations were explained due to the overproduction of MMPs, such as interstitial collagenase-1 (MMP-1) breaking down elastin, fibrillar collagens and other connective components; therefore, the skin loses its ability to resist the stretching (Rui et al., 2019). Berthon et al. (2017) reported that the

cumulating of ROS and inflammatory responses resulted in excessive MMPs. In the current study, SE suppressed the levels of MMP-1.

Hydroxyproline content of skin tissue, which was regarded as characteristic amino acid of collagen and represents changes in collagen content (Kakinuma et al., 2005). The results indicated that the levels of Hyp were significantly improved in the SE-treated groups maintaining intact structures in the dermis and epidermis and a tight arrangement of cells. In agreement with Ragusa et al. (2021), this change in collagen content can be attributed to the SE content of several bioactive compounds, particularly proteins (67.6%), which are involved in many physiological processes, including inflammation, immune response and skin remodeling, and they also stimulate the synthesis of structural proteins (collagen and elastin). For the same purpose, a *Spirulina* peptide extract showed obvious dermatological effects on the inducement of fibroblast reproduction as well as on the biosynthesis of glycosaminoglycans and collagen (Aguilar-Toalá et al., 2019). Additionally, it has been reported that peptides extracted from *Spirulina platensis* have anti-skin aging effects (Ovando et al., 2018).

Conclusions

In conclusion, the subcutaneous injection of SE significantly showed anti-aging effects, mediated by anti-oxidation, anti-inflammation and MMP-1 inhibition in chronological and photoaged skin of albino rats. Additionally, for the first time SE was demonstrated to increase the production of collagen on both intrinsic and extrinsic aging. This suggests that SE could relieve inflammation response and promote immune protection against skin aging in addition to enhancing collagen biosynthesis. These results suggest that SE is a useful material for application in dermo-cosmetic formulations for the improvement of the epidermis structure and for conserving the skin from the devastating effects of aging and UV exposure.

Abbreviations

SE	Spirulina extract
UVA	Ultraviolet A
(NF)-κB	Nuclear factor
ANOVA	Analysis of variance
AP-1	Activator protein-1
CAT	Catalase
ECM	Extracellular matrix
ELISA	Enzyme-linked immunosorbent assay
GSH	Glutathione
GSH-Px	Glutathione peroxidase
H&E	Hematoxylin and eosin
H2O2	Hydrogen peroxide
Hyp	Hydroxyproline
IL-1β	Interleukin-1β
MAPK	Mitogen-activated protein kinase
MMPs	Matrix metalloproteinases
PBS	Phosphate-buffered saline
ROS	Reactive oxygen species
SOD	Superoxide dismutase
TNF-α	Tumor necrosis factor-α

Acknowledgements

Not applicable.

Author contributions

KS create the idea and supervise all steps. All authors wrote the main manuscript text, and HM prepared figures and tables. KH and AM reviewed the manuscript. SS save laboratory space and equipment.

Funding

The authors have not received any funds.

Availability of data and materials

The datasets generated during and/or analyzed during the current study are included in this published article.

Declarations

Ethics approval and consent to participate

The method of this manuscript adheres to ARRIVE guidelines. The protocol for conducting the acute and in vivo studies was performed according to the guidelines of the care and use of laboratory animals (8th edition), and the study was approved by the Institutional Ethics Committee for animal care and use (ZD/FSc/BU-IACUC/2022-13) of the Faculty of Science, Benha University, Egypt (Method, page 5/4).

Consent for publication

All authors have agreed to publish this manuscript.

Competing interests

The author(s) declare no competing interests.

Received: 17 August 2023 Accepted: 12 September 2023
Published online: 18 September 2023

References

Aguilar-Toalá, J. E., Hernández-Mendoza, A., González-Córdova, A. F., Vallejo-Cordoba, B., & Liceaga, A. M. (2019). Potential role of natural bioactive peptides for development of cosmeceutical skin products. *Peptides, 122*, 170170. https://doi.org/10.1016/j.peptides.2019.170170

Amer, N. S. (2018). Productive performance and immune response in growing Japanese quail supplemented with spirulina algae extract (*Arthrospira platensis*) in drinking water. *Egyptian Poultry Science Journal, 38*(2), 409–426.

Berthon, J. Y., Nachat-Kappes, R., Bey, M., Cadoret, J. P., Renimel, I., & Filaire, E. (2017). Marine algae as attractive source to skin care. *Free Radical Research, 51*(6), 555–567.

Beutler, E., Duron, O., & Kelly, B. M. (1963). Improved method for the determination of blood glutathione. *The Journal of Laboratory and Clinical Medicine, 61*, 882–888.

Campanini, M. Z., Pinho-Ribeiro, F. A., Ivan, A. L., Ferreira, V. S., Vilela, F. M., Vicentini, F. T., Martinez, R. M., Zarpelon, A. C., Fonseca, M. J., Faria, T. J., & Casagrande, R. (2013). Efficacy of topical formulations containing *Pimenta pseudocaryophyllus* extract against UVB-induced oxidative stress and inflammation in hairless mice. *Journal of Photochemistry and Photobiology B: Biology, 127*, 153–160. https://doi.org/10.1016/j.jphotobiol.2013.08.007

D'Orazio, J., Jarrett, S., Amaro-Ortiz, A., & Scott, T. (2013). UV radiation and the skin. *International Journal of Molecular Sciences, 14*(6), 12222–12248. https://doi.org/10.3390/ijms140612222

Duan, W., Qiao, S., Zhuo, M., Sun, J., Guo, M., Xu, F., Liu, J., Wang, T., Guo, X., Zhang, Y., Gao, J., & Chen, Y. (2021). Multifunctional platforms:

metal-organic frameworks for cutaneous and cosmetic treatment. *Chem, 7*(2), 450–462. https://doi.org/10.1016/j.chempr.2020.11.018
Duncan, D. B. (1957). Multiple range tests for correlated and heteroscedastic means. *Biometrics, 13*(2), 164. https://doi.org/10.2307/2527799
Grover, P., Bhatnagar, A., Kumari, N., Narayan Bhatt, A., Kumar Nishad, D., & Purkayastha, J. (2021). C-phycocyanin-A novel protein from spirulina platensis- in vivo toxicity, antioxidant and immunomodulatory studies. *Saudi Journal of Biological Sciences, 28*(3), 1853–1859. https://doi.org/10.1016/j.sjbs.2020.12.037
Kakinuma, M., Watanabe, Y., Hori, Y., Ohi, T., & Tsuboi, R. (2005). Quantification of hydroxyproline in small amounts of skin tissue using isocratic high performance liquid chromatography with NBD-F as fluorogenic reagent. *Journal of Chromatography B, 824*(1–2), 161–165. https://doi.org/10.1016/j.jchromb.2005.07.019
Kammeyer, A., & Luiten, R. M. (2015). Oxidation events and skin aging. *Ageing Research Reviews, 21*, 16–29. https://doi.org/10.1016/j.arr.2015.01.001
Kesava Reddy, G., & Enwemeka, C. S. (1996). A simplified method for the analysis of Hydroxyproline in biological tissues. *Clinical Biochemistry, 29*(3), 225–229. https://doi.org/10.1016/0009-9120(96)00003-6
Koracevic, D., Koracevic, G., Djordjevic, V., Andrejevic, S., & Cosic, V. (2001). Method for the measurement of antioxidant activity in human fluids. *Journal of Clinical Pathology, 54*(5), 356–361. https://doi.org/10.1136/jcp.54.5.356
Krutmann, J., Schikowski, T., Morita, A., & Berneburg, M. (2021). Environmentally-induced (extrinsic) skin aging: Exposomal factors and underlying mechanisms. *Journal of Investigative Dermatology, 141*(4), 1096–1103. https://doi.org/10.1016/j.jid.2020.12.011
Kulshreshtha, A., Jarouliya, U., Bhadauriya, P., Prasad, G. B. K. S., & Bisen, P. S. (2008). Spirulina in health care management. *Current Pharmaceutical Biotechnology, 9*(5), 400–405. https://doi.org/10.2174/138920108785915111
Lee, C. M., Watson, R. E. B., & Kleyn, C. E. (2020). The impact of perceived stress on skin ageing. *Journal of the European Academy of Dermatology and Venereology, 34*(1), 54–58. https://doi.org/10.1111/jdv.15865
Lephart, E. D. (2016). Skin aging and oxidative stress: Equol's anti-aging effects via biochemical and molecular mechanisms. *Ageing Research Reviews, 31*, 36–54. https://doi.org/10.1016/j.arr.2016.08.001
Letsiou, S. (2021). Tracing skin aging process: A mini-review of in vitro approaches. *Biogerontology, 22*(3), 261–272. https://doi.org/10.1007/s10522-021-09916-z
Mendiola, J. A., Jaime, L., Santoyo, S., Reglero, G., Cifuentes, A., Ibañez, E., & Señoráns, F. J. (2007). Screening of functional compounds in supercritical fluid extracts from Spirulina platensis. *Food Chemistry, 102*(4), 1357–1367. https://doi.org/10.1016/j.foodchem.2006.06.068
Nishikimi, M., Rao, N. A., & Yagi, K. (1972). The occurrence of superoxide anion in the reaction of reduced phenazine methosulfate and molecular oxygen. *Biochemical and Biophysical Research Communications, 46*(2), 849–854. https://doi.org/10.1016/s0006-291x(72)80218-3
Ovando, C. A., Carvalho, J. C. D., de Melo, V., Pereira, G., Jacques, P., Soccol, V. T., & Soccol, C. R. (2018). Functional properties and health benefits of bioactive peptides derived from Spirulina: A review. *Food Reviews International, 34*(1), 34–51. https://doi.org/10.1080/87559129.2016.1210632
Pereira, L. (2018). Seaweeds as source of bioactive substances and skin care therapy—Cosmeceuticals, algotheraphy, and thalassotherapy. *Cosmetics, 5*(4), 68. https://doi.org/10.3390/cosmetics5040068
Pillai, S., Oresajo, C., & Hayward, J. (2005). Ultraviolet radiation and skin aging: Roles of reactive oxygen species, inflammation and protease activation, and strategies for prevention of inflammation-induced matrix degradation–a review. *International Journal of Cosmetic Science, 27*(1), 17–34. https://doi.org/10.1111/j.1467-2494.2004.00241.x
Pittayapruek, P., Meephansan, J., Prapapan, O., Komine, M., & Ohtsuki, M. (2016). Role of matrix metalloproteinases in photoaging and photocarcinogenesis. *International Journal of Molecular Sciences, 17*(6), 868. https://doi.org/10.3390/ijms17060868
Poljšak, B., Dahmane, R. G., & Godić, A. (2012). Intrinsic skin aging: The role of oxidative stress. *Acta Dermatovenerol Alp Pannonica Adriat, 21*(2), 33–36.
Prasedya, E. S., Syafitri, S. M., Geraldine, B. A., Hamdin, C. D., Frediansyah, A., Miyake, M., Kobayashi, D., Hazama, A., & Sunarpi, H. (2019). UVA photoprotective activity of brown macroalgae *Sargassum cristafolium*. *Biomedicines, 7*(4), 77. https://doi.org/10.3390/biomedicines7040077
Proksch, E., Brandner, J. M., & Jensen, J.-M. (2008). The skin: An indispensable barrier. *Experimental Dermatology, 17*(12), 1063–1072. https://doi.org/10.1111/j.1600-0625.2008.00786.x
Ragusa, I., Nardone, G. N., Zanatta, S., Bertin, W., & Amadio, E. (2021). Spirulina for skin care: A bright blue future. *Cosmetics, 8*(1), 7. https://doi.org/10.3390/cosmetics8010007
Rincón-Fontán, M., Rodríguez-López, L., Vecino, X., Cruz, J. M., & Moldes, A. B. (2020). Potential application of a multifunctional biosurfactant extract obtained from corn as stabilizing agent of vitamin C in cosmetic formulations. *Sustainable Chemistry and Pharmacy, 16*, 100248. https://doi.org/10.1016/j.scp.2020.100248
Rui, Y., Zhaohui, Z., Wenshan, S., Bafang, L., & Hu, H. (2019). Protective effect of MAAs extracted from *Porphyra tenera* against UV irradiation-induced photoaging in mouse skin. *Journal of Photochemistry and Photobiology B: Biology, 192*, 26–33. https://doi.org/10.1016/j.jphotobiol.2018.12.009
Shin, J. W., Kwon, S. H., Choi, J. Y., Na, J. I., Huh, C. H., Choi, H. R., & Park, K. C. (2019). Molecular mechanisms of dermal aging and antiaging approaches. *International Journal of Molecular Sciences, 20*(9), 2126. https://doi.org/10.3390/ijms20092126
Sjerobabski-Masnec, I., & Situm, M. (2010). Skin aging. *Acta Clinica Croatica, 49*(4), 515–518.
Takach, E. (2013). Tissue homogenization. *Tissue Analysis for Drug Development*. https://doi.org/10.4155/ebo.13.457
Wang, X. F., Huang, Y. F., Wang, L., Xu, L. Q., Yu, X. T., Liu, Y. H., Li, C. L., Zhan, J. Y. X., Su, Z. R., Chen, J. N., & Zeng, H. F. (2016). Photo-protective activity of pogostone against UV-induced skin premature aging in mice. *Experimental Gerontology, 77*, 76–86. https://doi.org/10.1016/j.exger.2016.02.017
Wu, Q., Liu, L., Miron, A., Klímová, B., Wan, D., & Kuča, K. (2016). The antioxidant, immunomodulatory, and anti-inflammatory activities of Spirulina: An overview. *Archives of Toxicology, 90*, 1817–1840. https://doi.org/10.1007/s00204-016-1744-5
Yogianti, F., Kunisada, M., Nakano, E., Ono, R., Sakumi, K., Oka, S., Nakabeppu, Y., & Nishigori, C. (2014). Inhibitory effects of dietary Spirulina platensis on UVB-induced skin inflammatory responses and carcinogenesis. *Journal of Investigative Dermatology, 134*(10), 2610–2619. https://doi.org/10.1038/jid.2014.188

Publisher's Note

Springer Nature remains neutral with regard to jurisdictional claims in published maps and institutional affiliations.

Submit your manuscript to a SpringerOpen journal and benefit from:

- ► Convenient online submission
- ► Rigorous peer review
- ► Open access: articles freely available online
- ► High visibility within the field
- ► Retaining the copyright to your article

Submit your next manuscript at ► springeropen.com